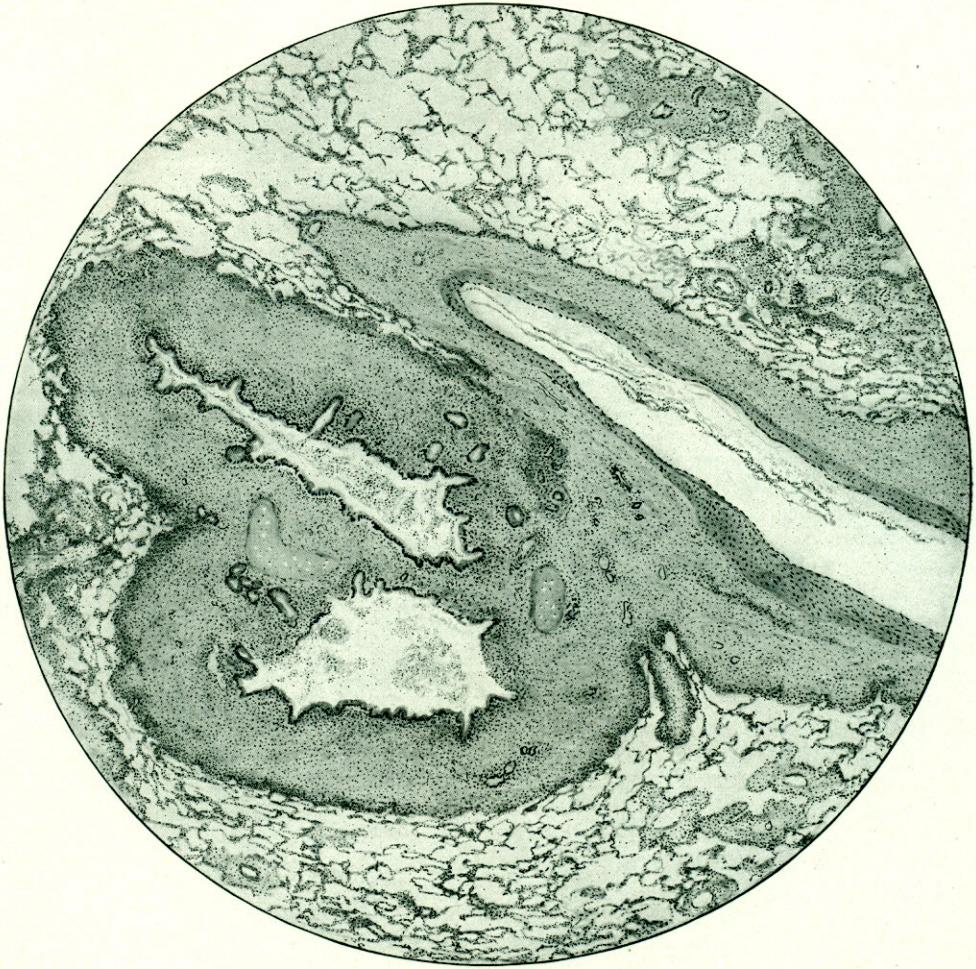

FIG. 43.—Case 106. Lung. Section (d), through thickened bronchi at hilum of lower lobe