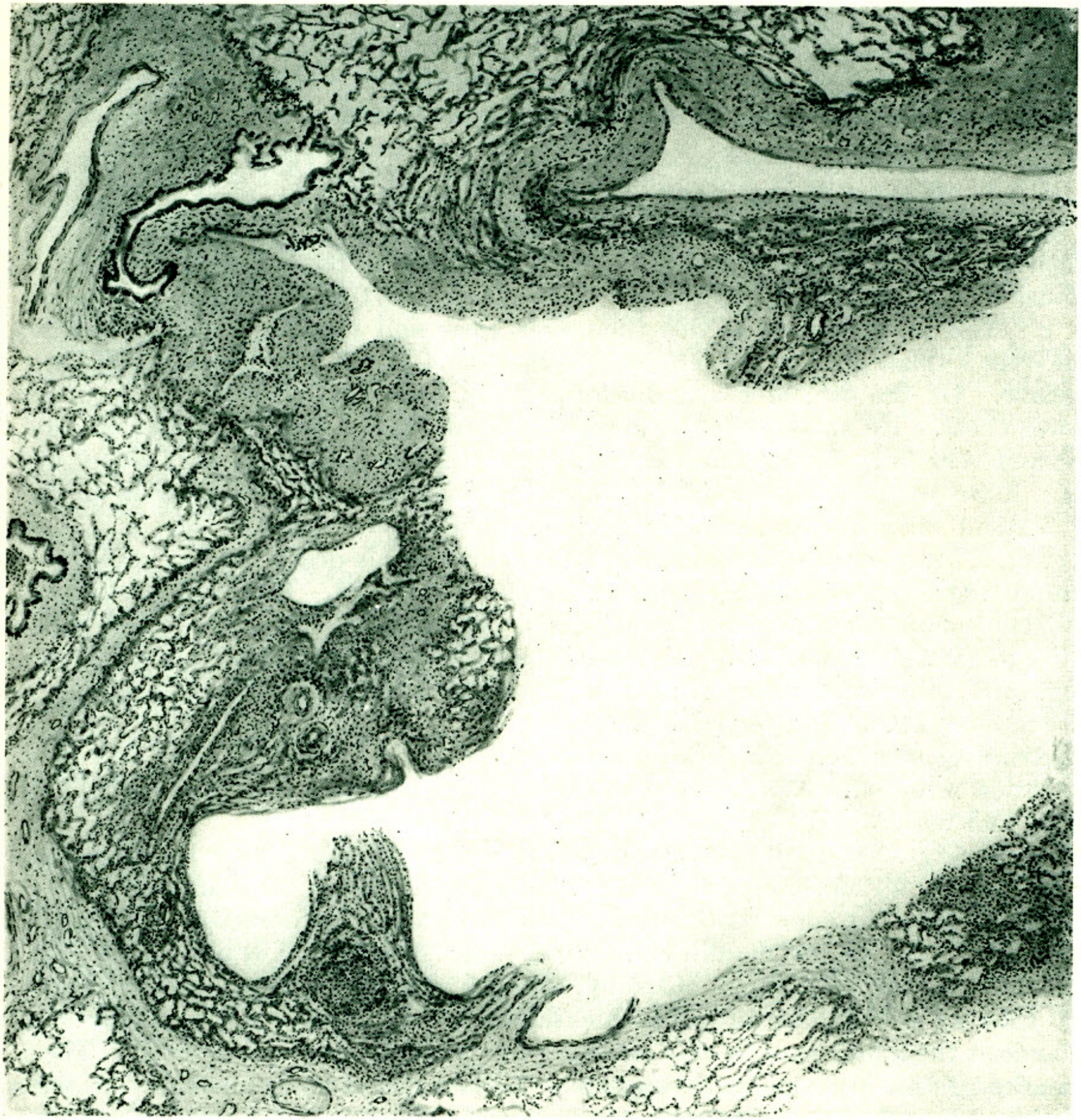

FIG. 38.—Case 103. Mustard-gas burn, 58 days' duration. Lung. Low-power drawing through bronchiectatic cavity. Peribronchial and periarterial fibrosis