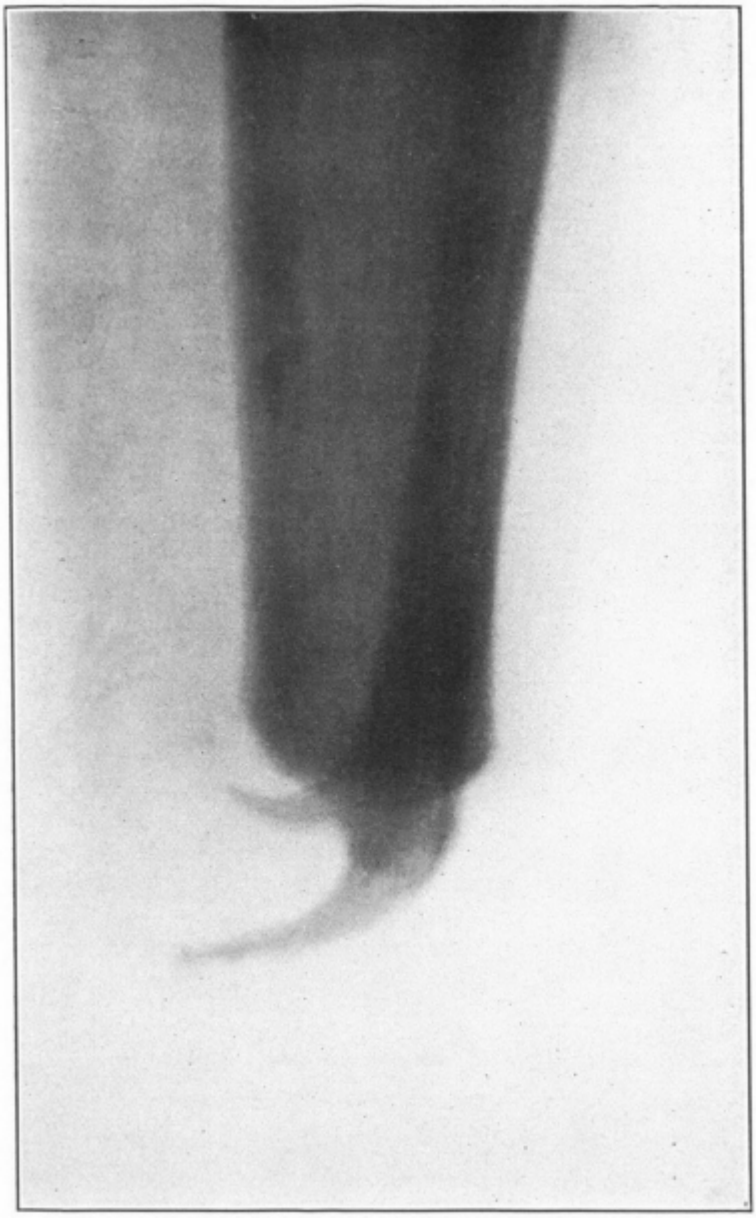

Fig. 163.—Bony spur in below-knee amputation