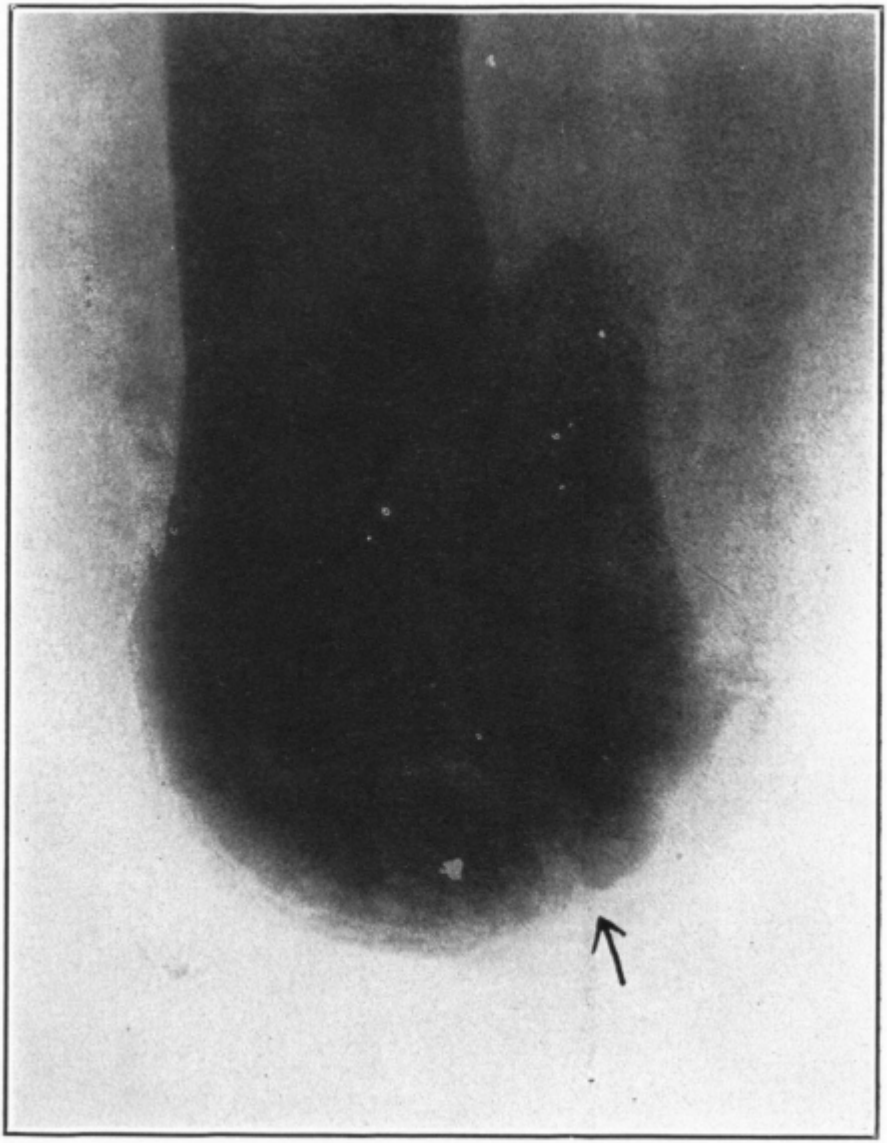

FIG. 161.—Complete ring sequestrum surrounded by new bone formation. The stump is healed except for small sinus from the sequestrum