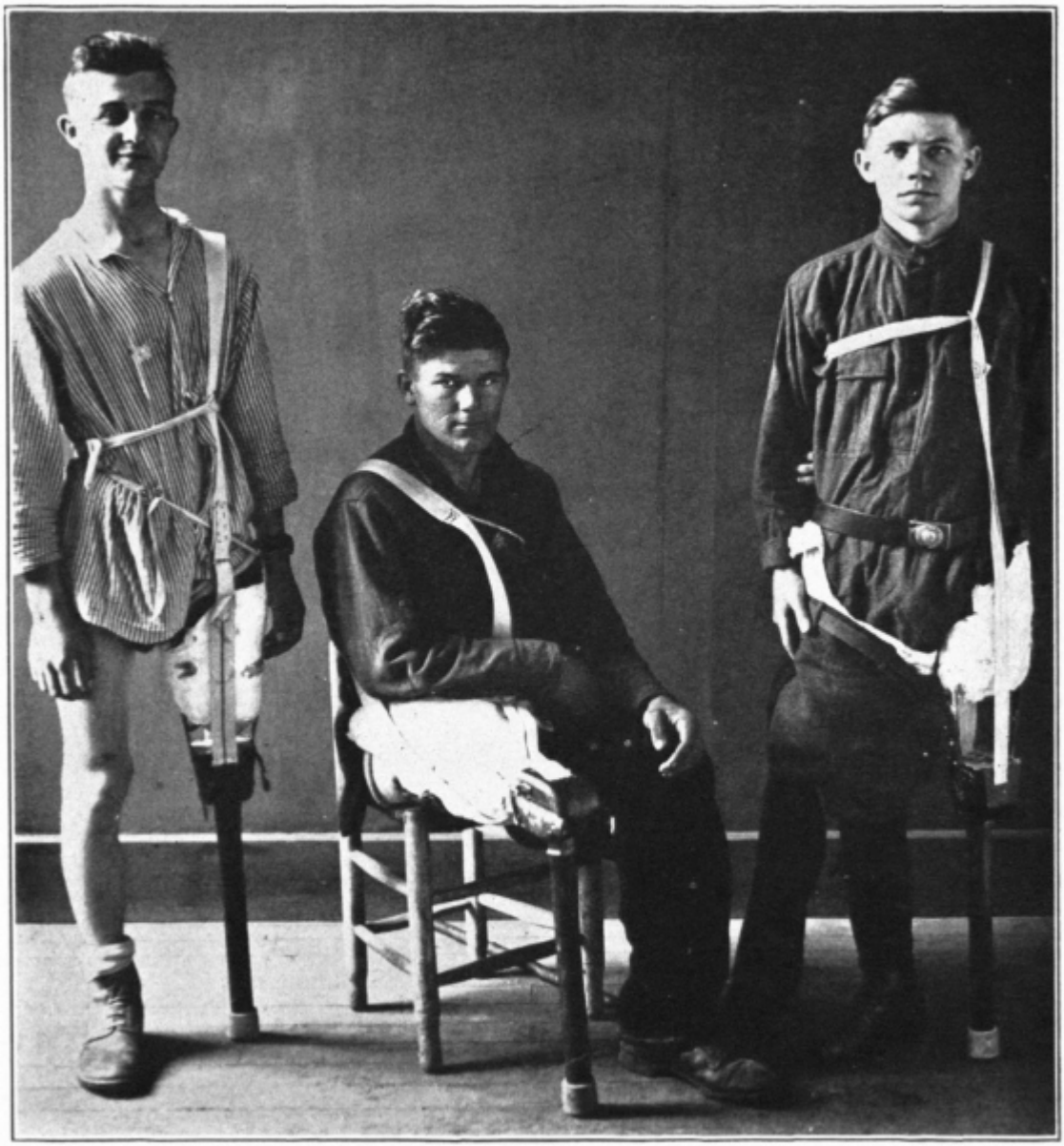

FIG. 144.—Patients with above-the-knee amputation fitted with the temporary peg leg with plaster socket