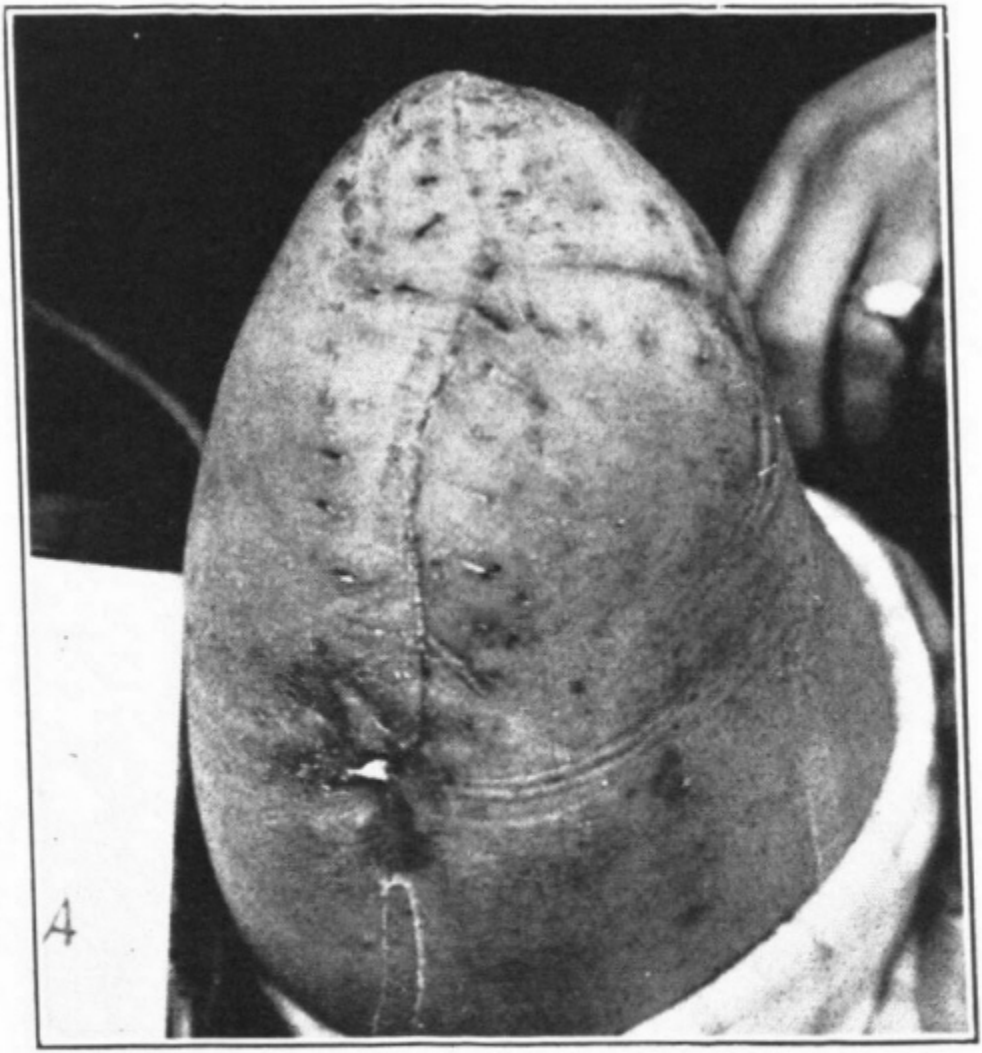

FIG. 138.—The same stump as that shown in Figure 137, after closure. The wound was excised, with a cone of tissue and the tip of the bone. The skin flaps were mobilized and drawn together