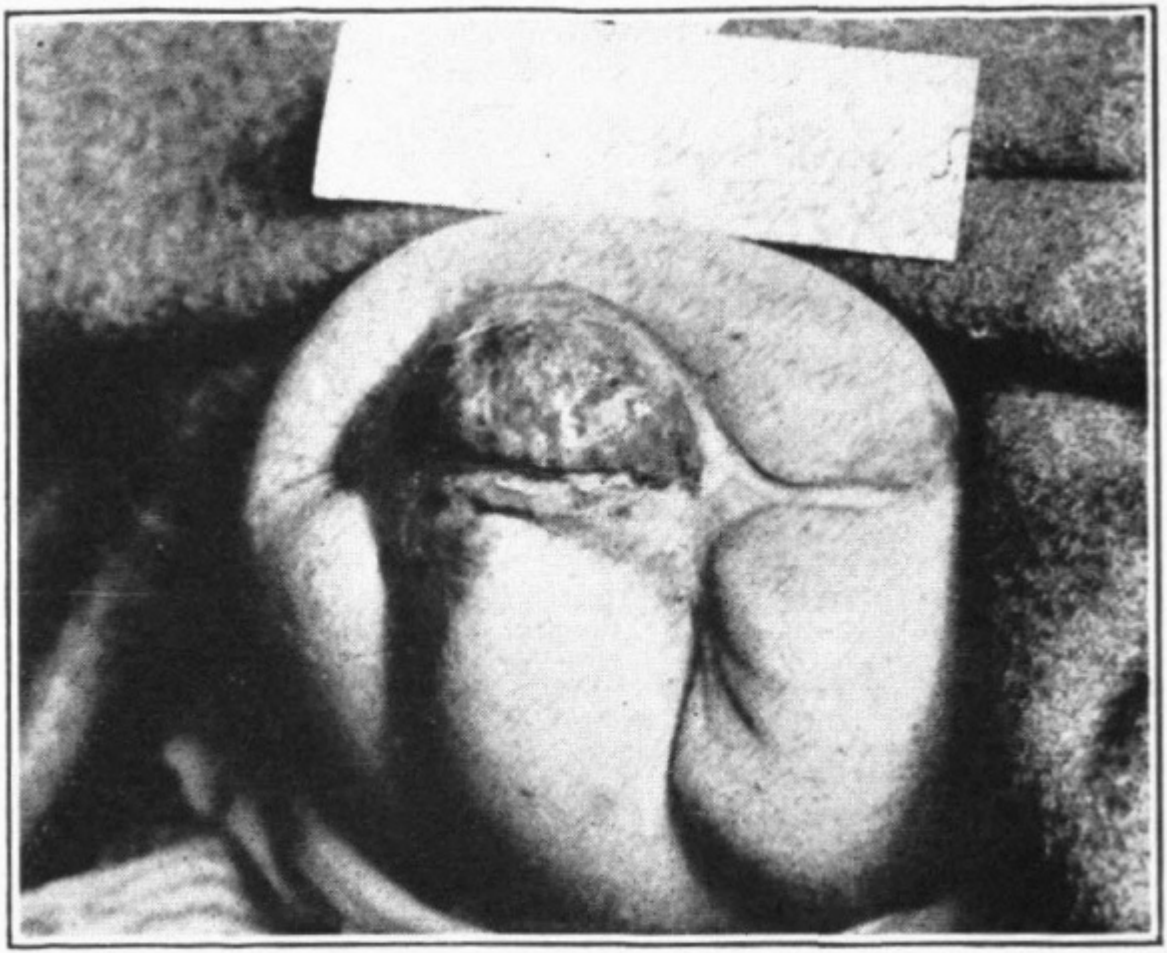

FIG. 136.—Short amputation of the thigh, with marked retraction of the soft parts and protrusion of the end of the bone covered by granulation tissue