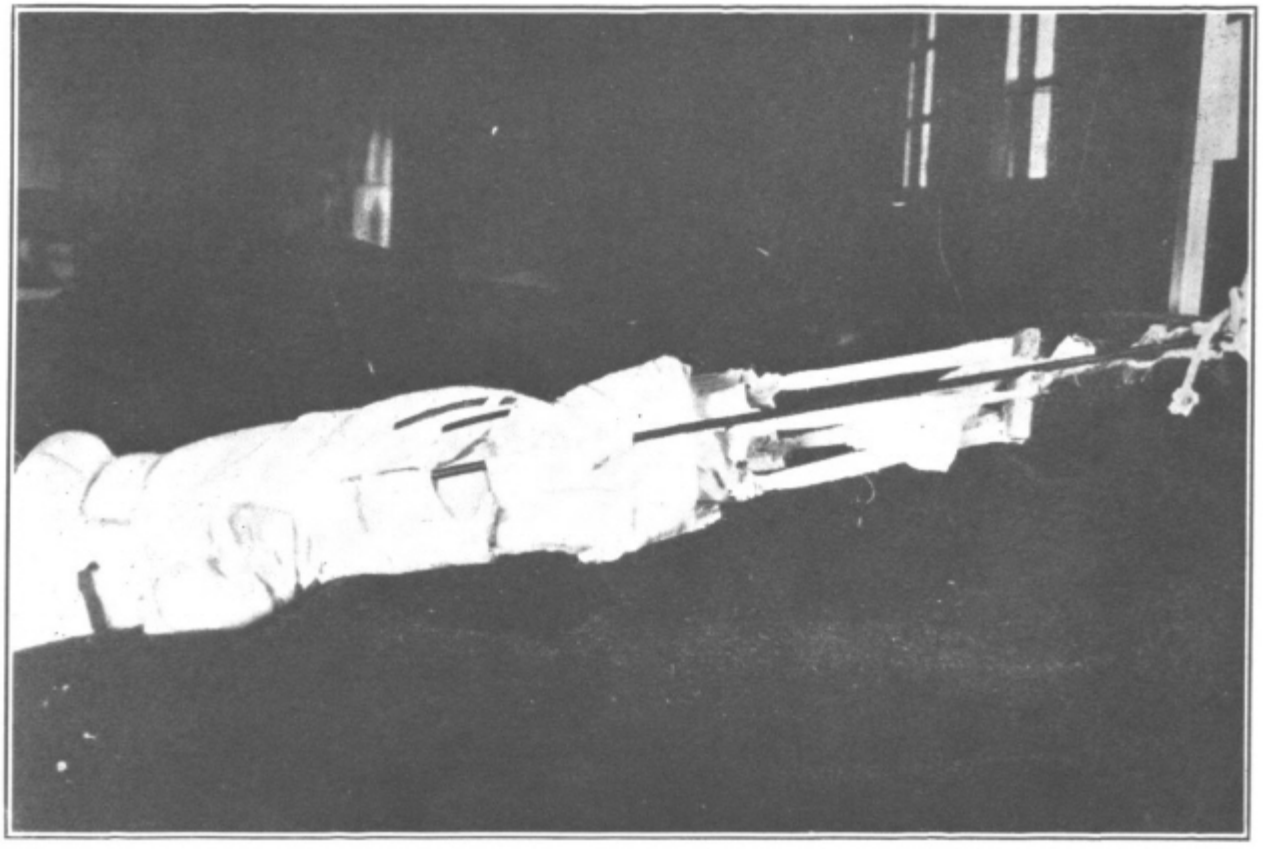

Fig. 129.—Use of Thomas splint in application of fixed extension to an amputation stump to overcome soft part retraction