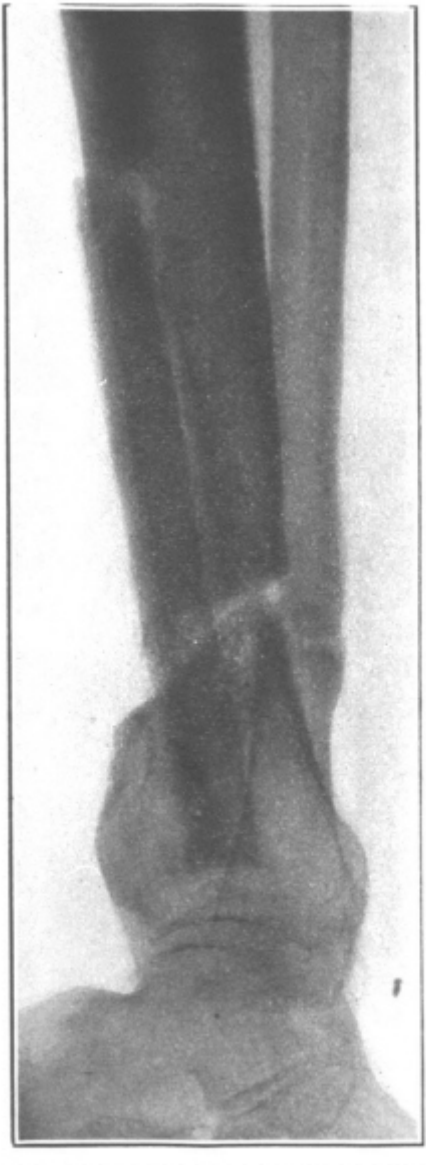

FIG. 127.—Case 15. Lateral roentgenogram three months after graft