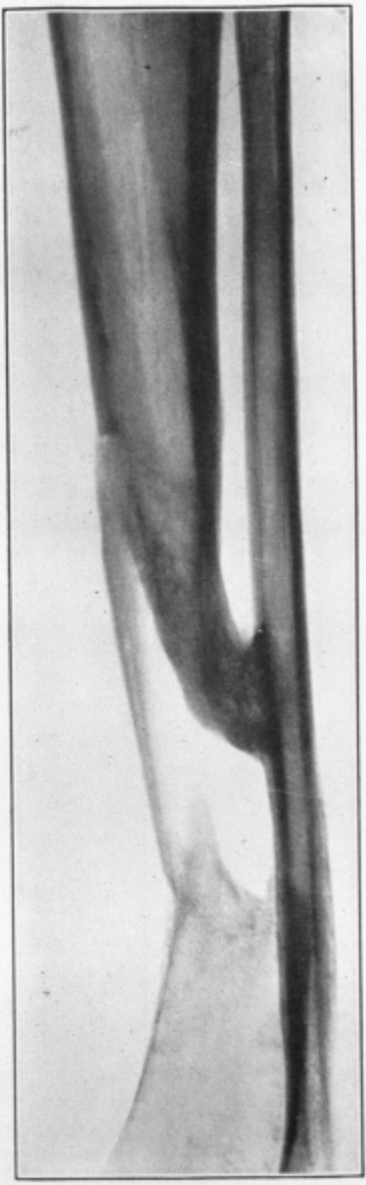

FIG. 124.—Case 14. Roentgenogram of graft six weeks after operation