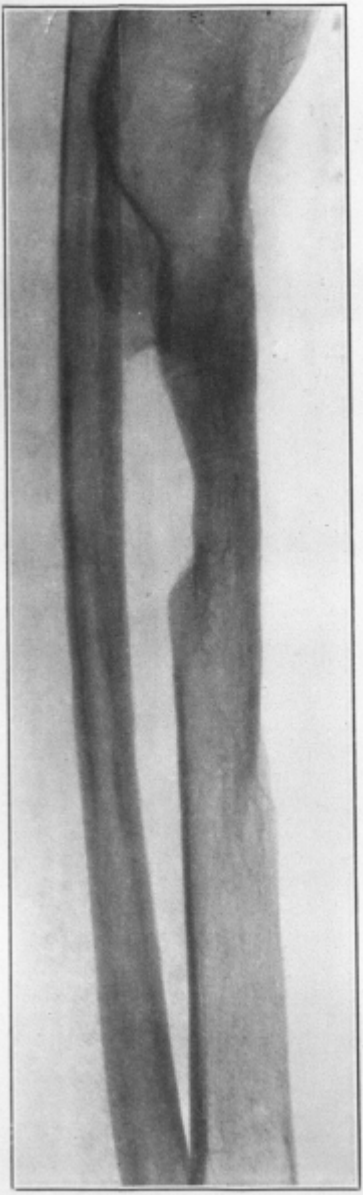

Fig. 123.—Case 13. Excellent union in old fracture in original graft and in new graft