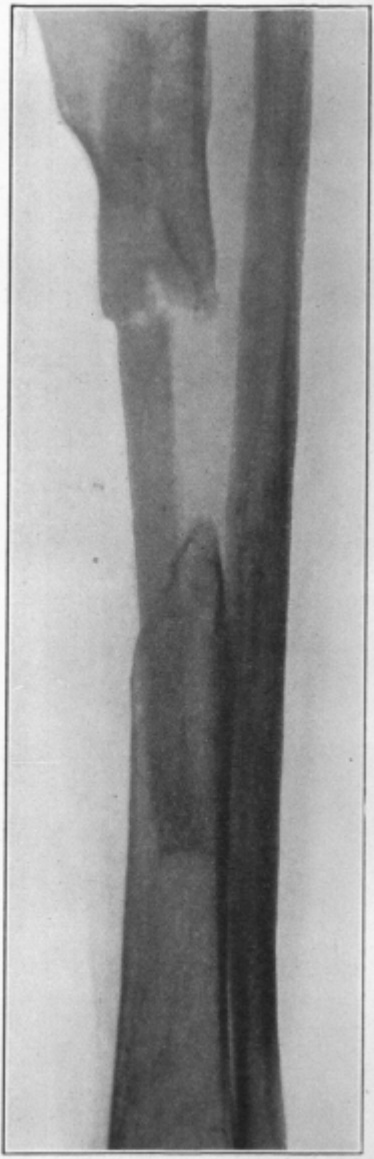

FIG. 122.—Case 13. Roentgenogram November 17, 1921, fracture of first graft during fourth month and loss of substance bridged by graft