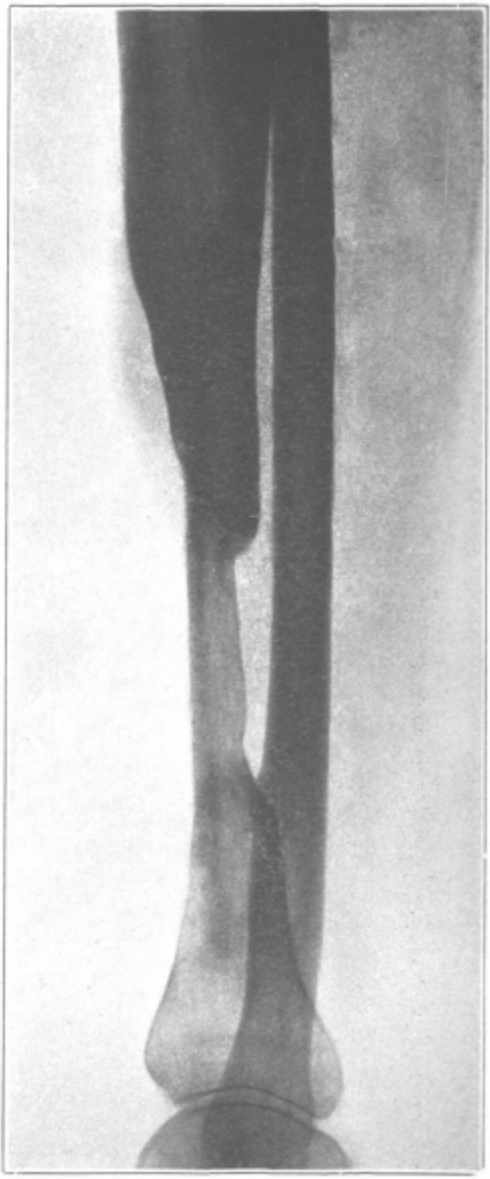

FIG. 118.—Case 12. Roentgenogram three months after graft