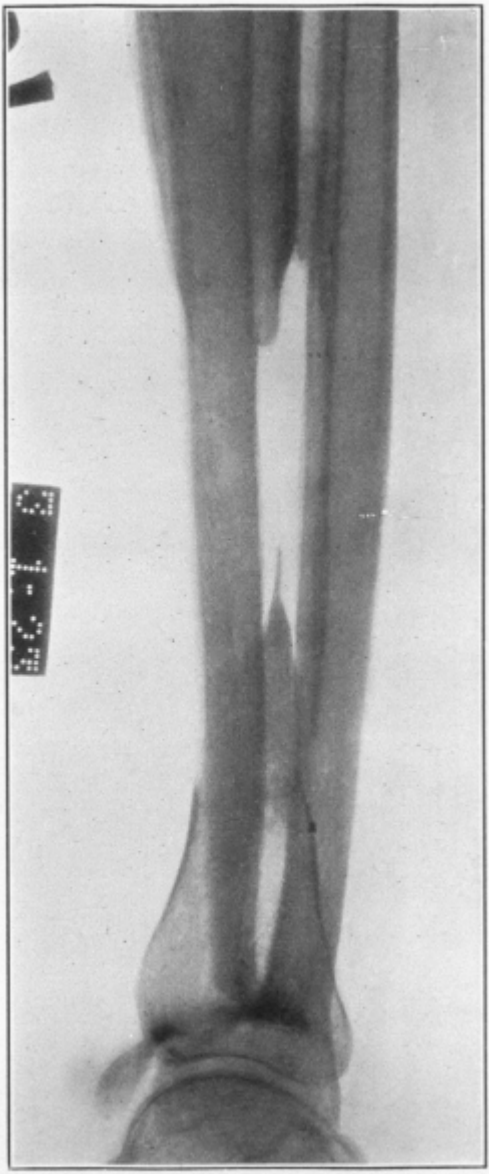

FIG. 116.—Case 11. Roentgenogram three months after graft showing excellent condition of bone