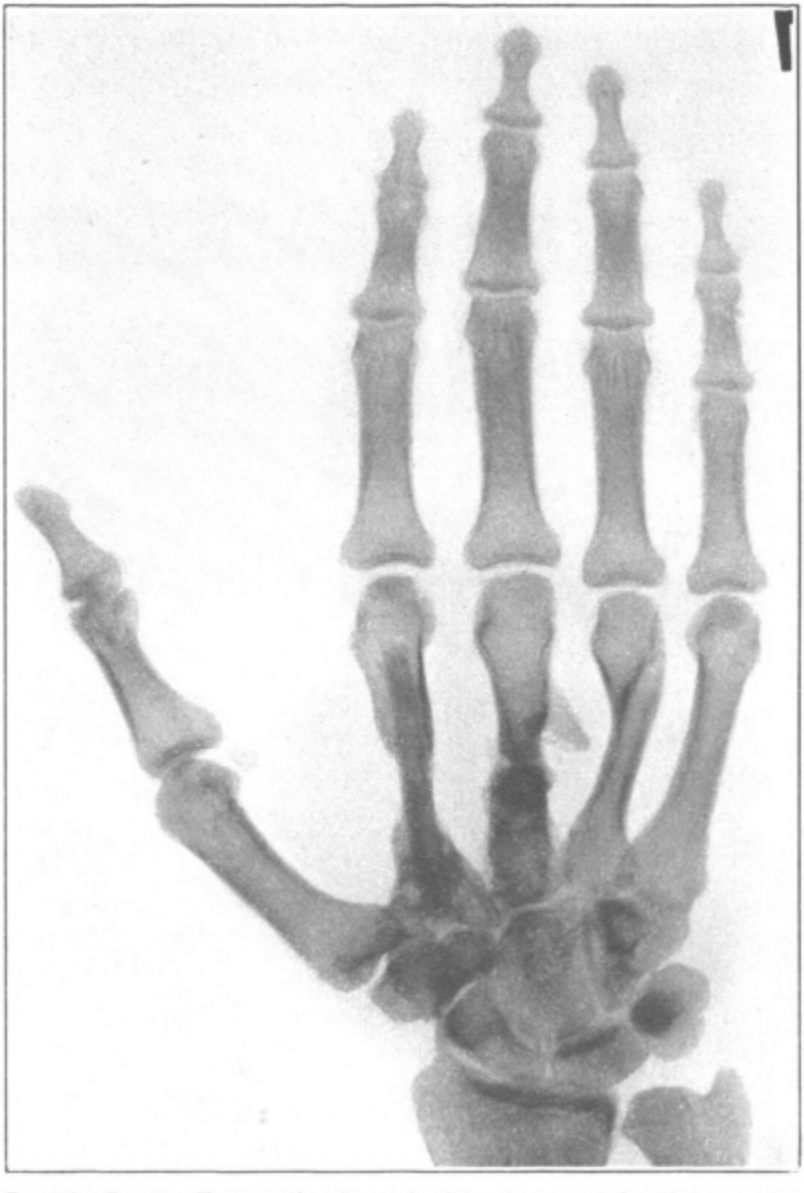

FIG. 112.—Case 10. Two months after graft—deformity corrected, with bony union