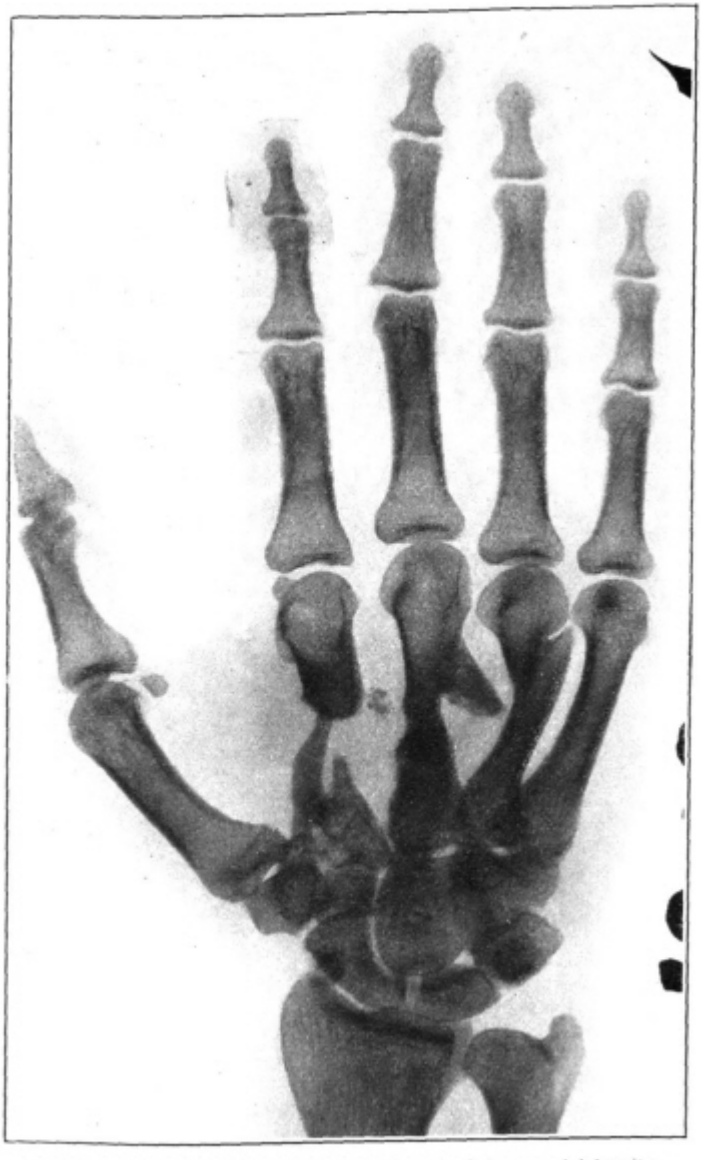

Fig. 111.—Case 10. Roentgenogram showing loss of substance and deformity