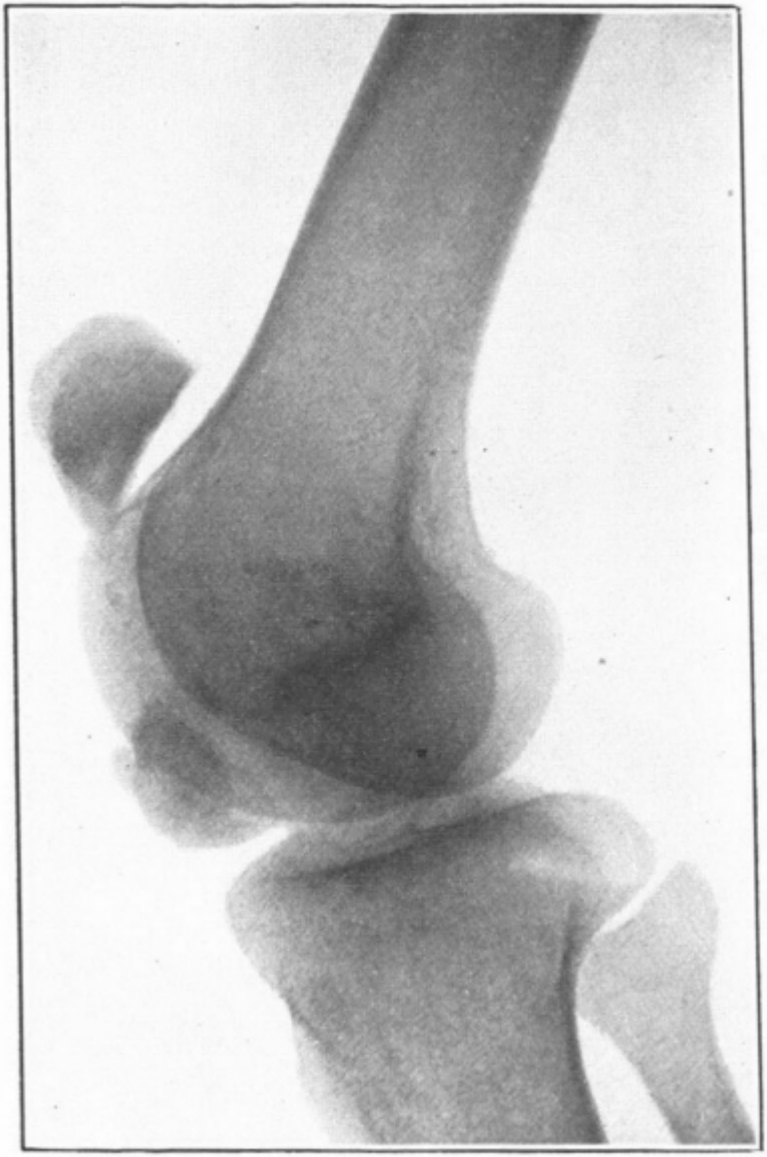

FIG. 109.—Case 9. Lateral view showing comminuted fracture of patella and separation of fragments