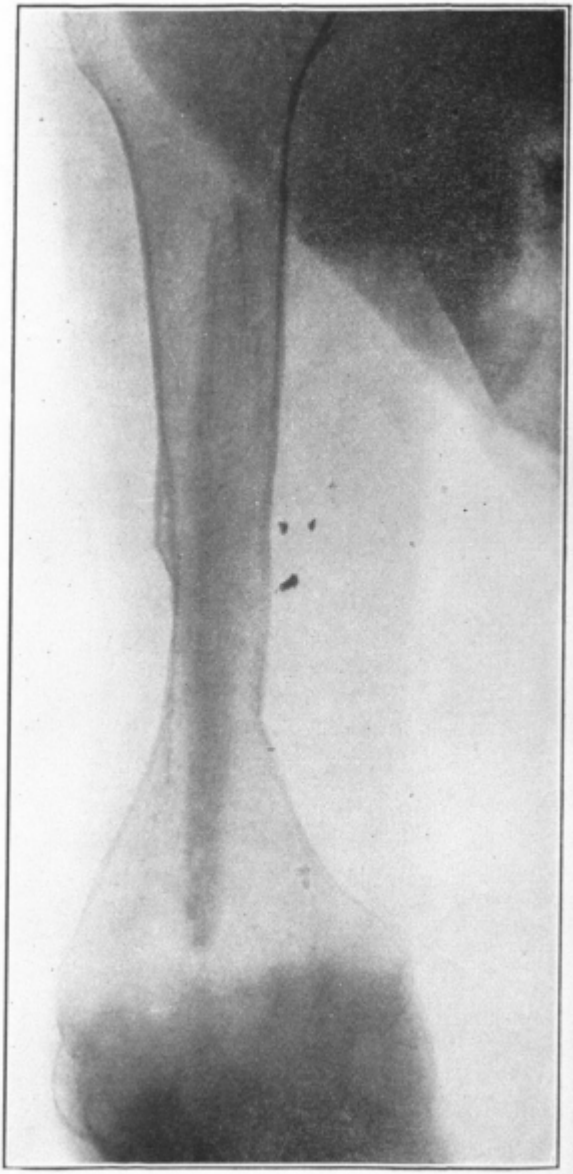

FIG. 108.—Case 8. Another view showing excellent bony union at end of six months