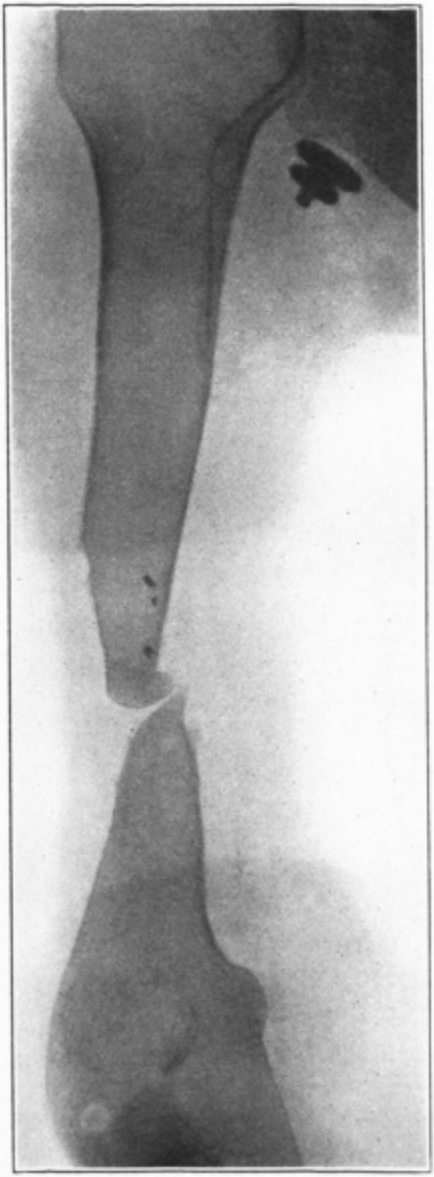

FIG. 106.—Case 8. Loss of substance and atrophy present in humerus before graft