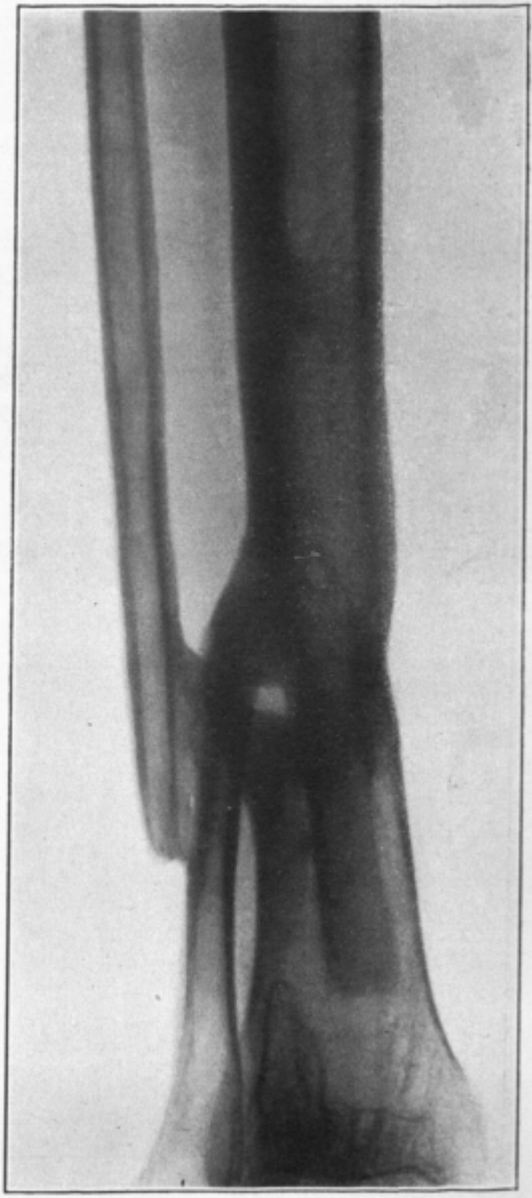

FIG. 98.—Case 5. Left tibia four months after graft