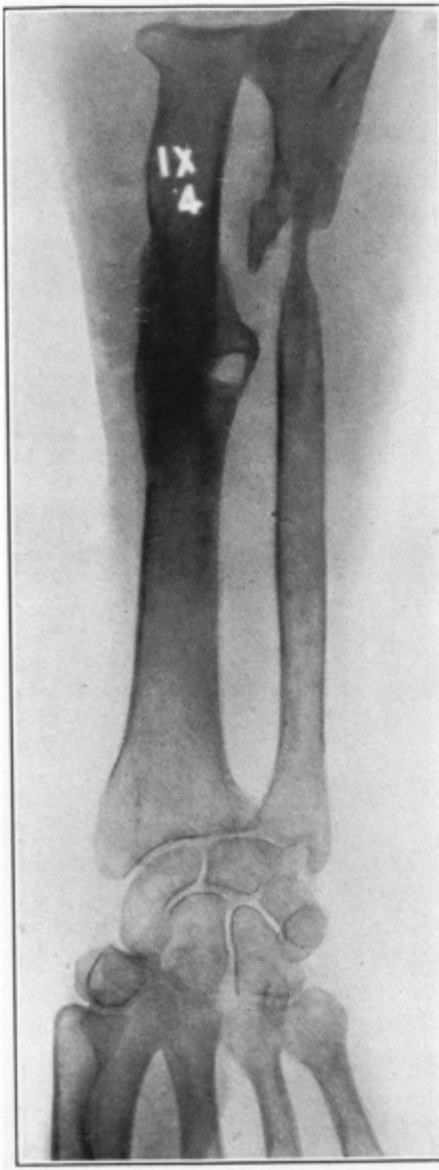

FIG. 91.—Case 2. March 23, 1921. Excellent bony union and hypertrophy of radius