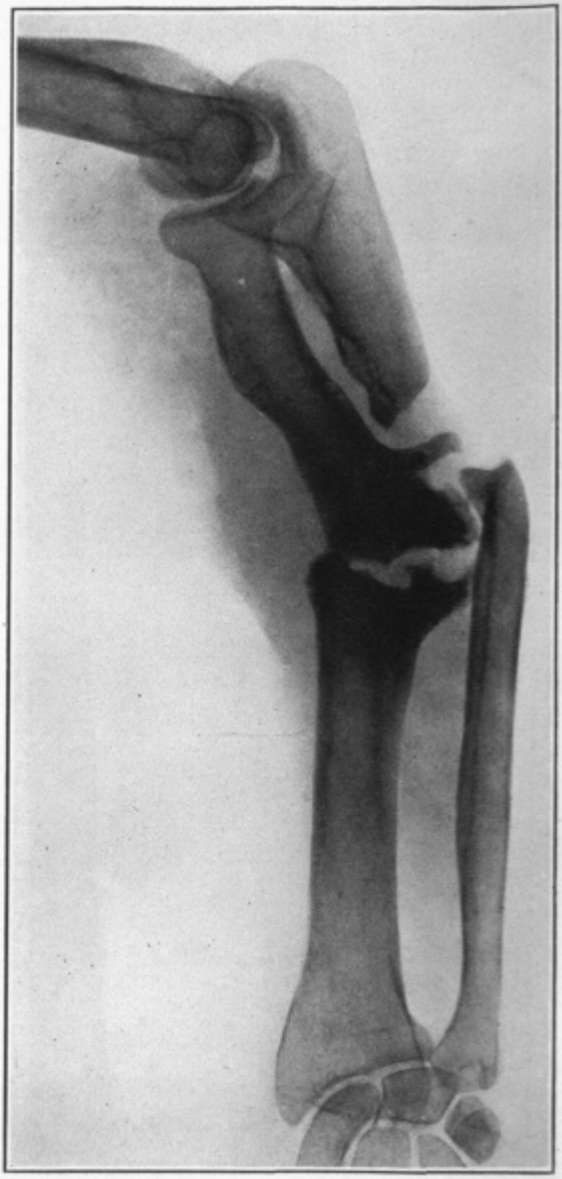

FIG. 89.—Case 2. Marked deformity and eburnation of bone ends where the pseudarthrosis had occurred