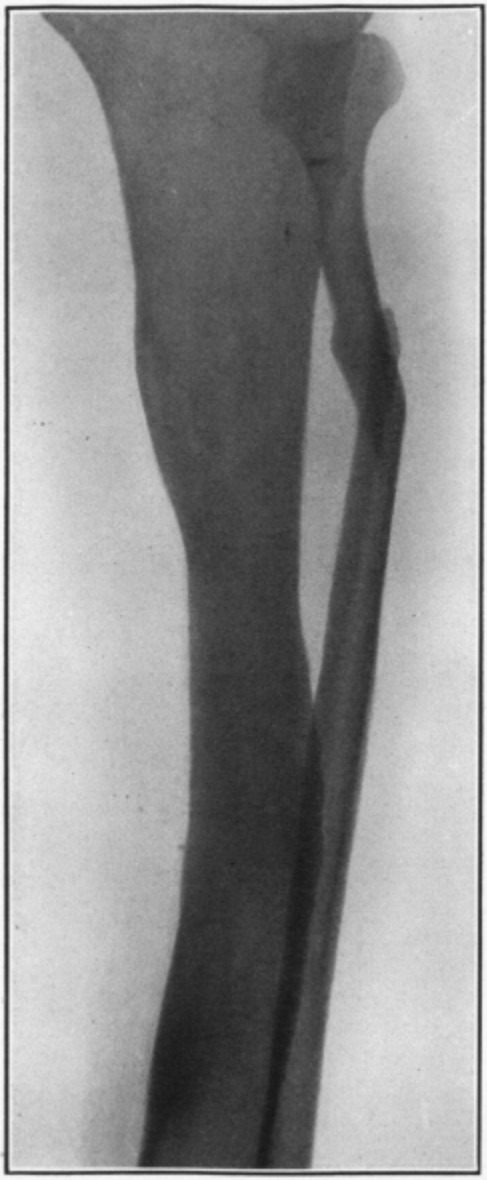

FIG. 88.—Case 1. Roentgenogram, May, 1924, showing hypertrophy of graft in tibia