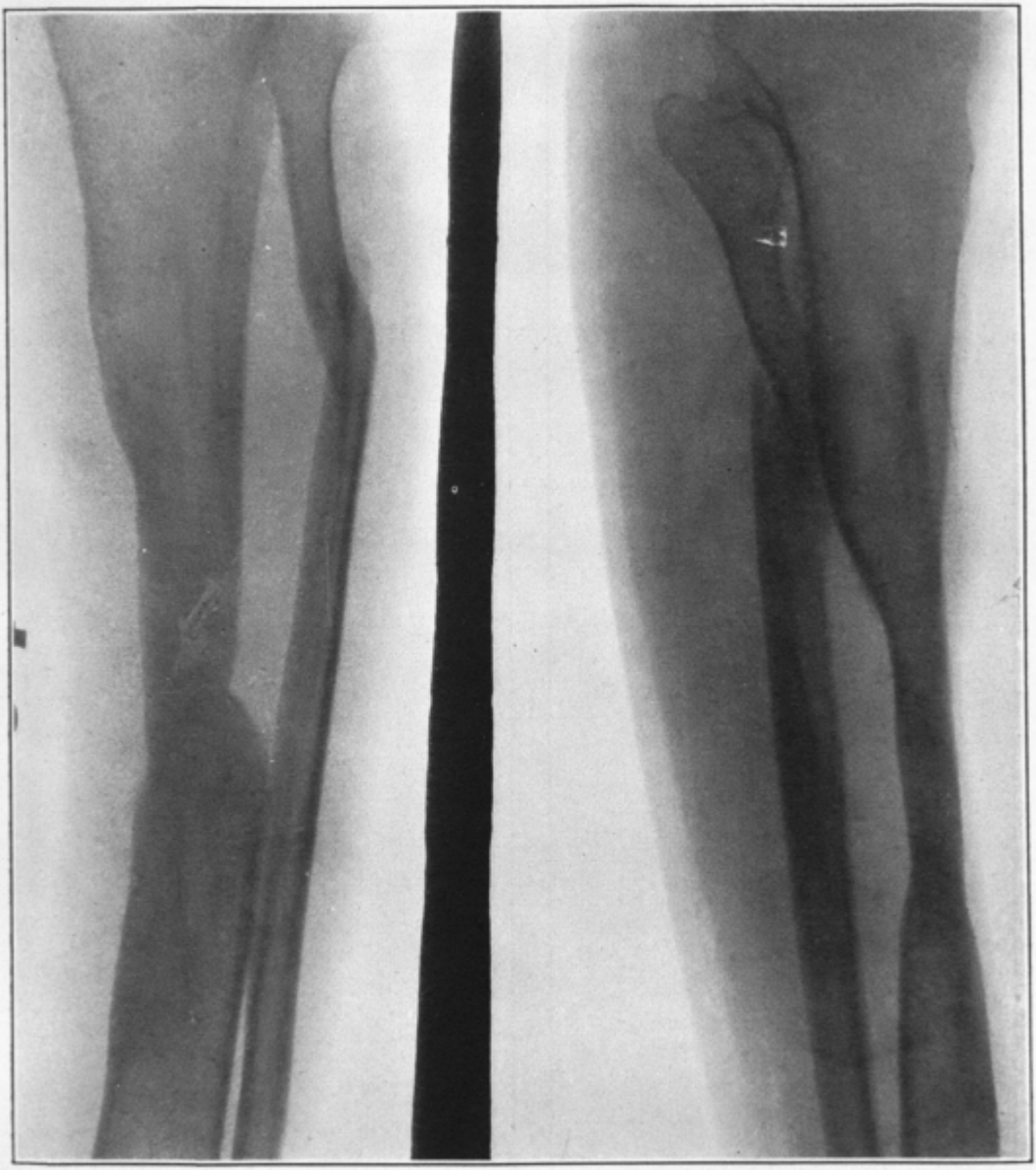

FIG. 87.—Case 1. August 1, 1922. Roentgenogram showing excellent bony union