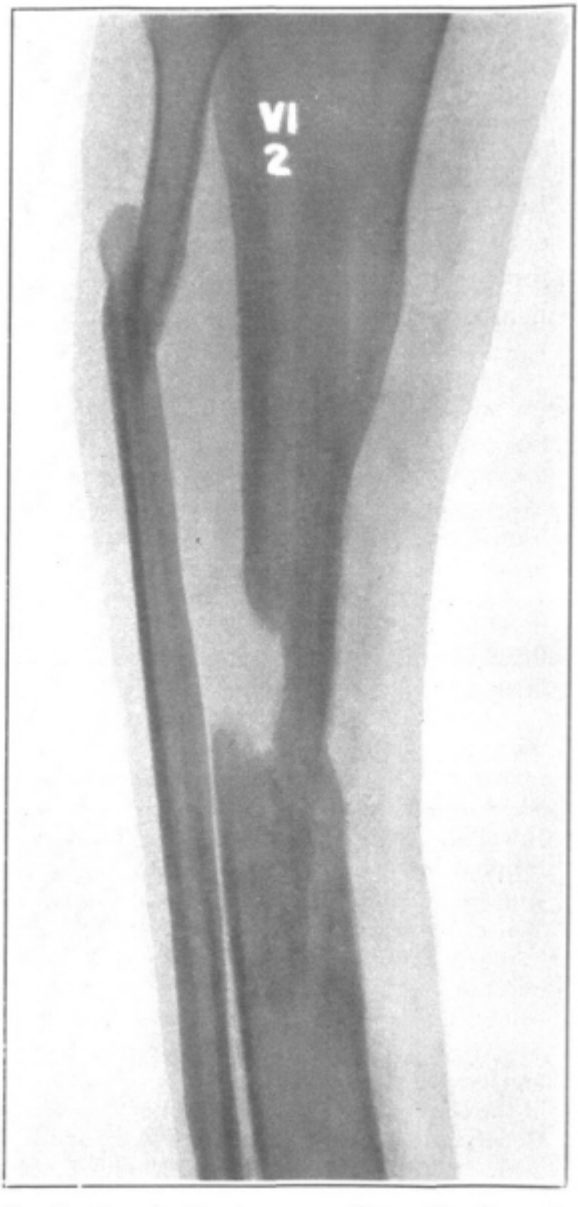

FIG. 86.—Case 1. Roentgenogram 3½ months after graft