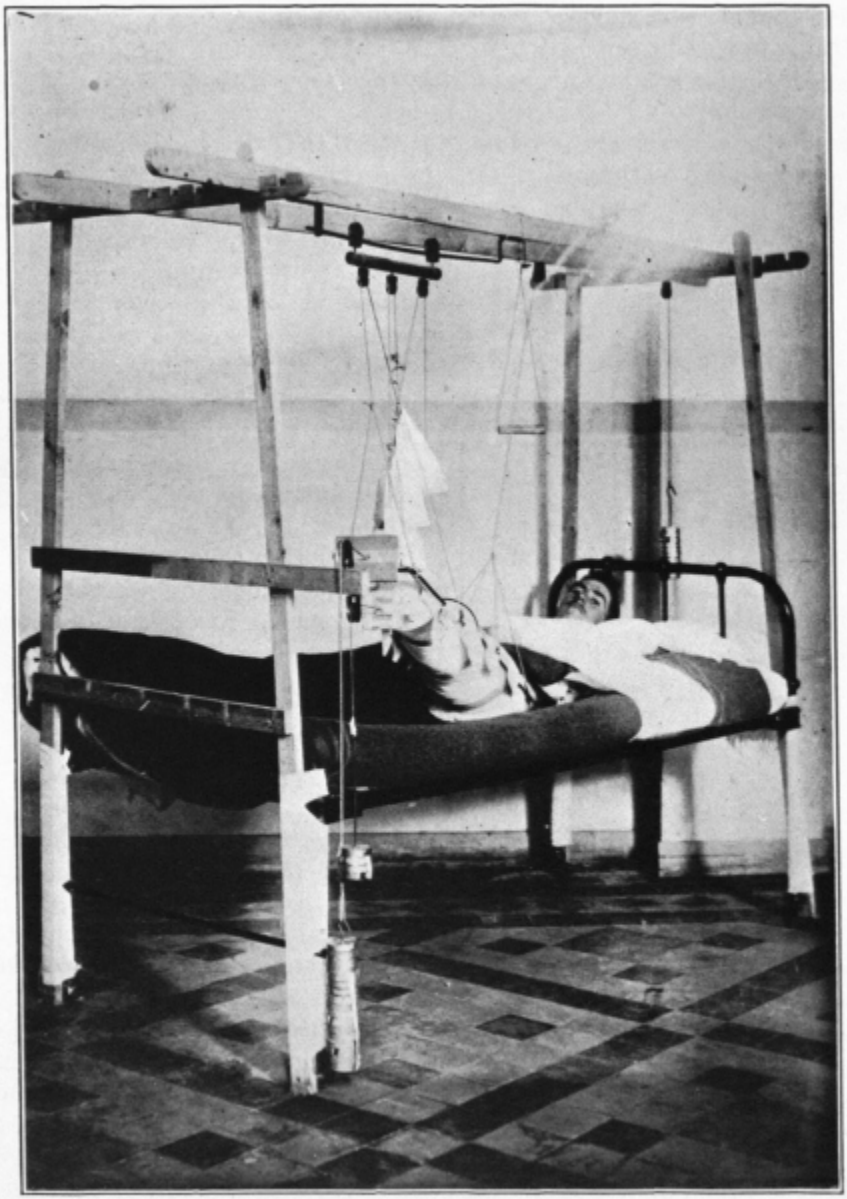

FIG. 78.—Fracture of femur, showing double extension. Inverted Hodgen splint