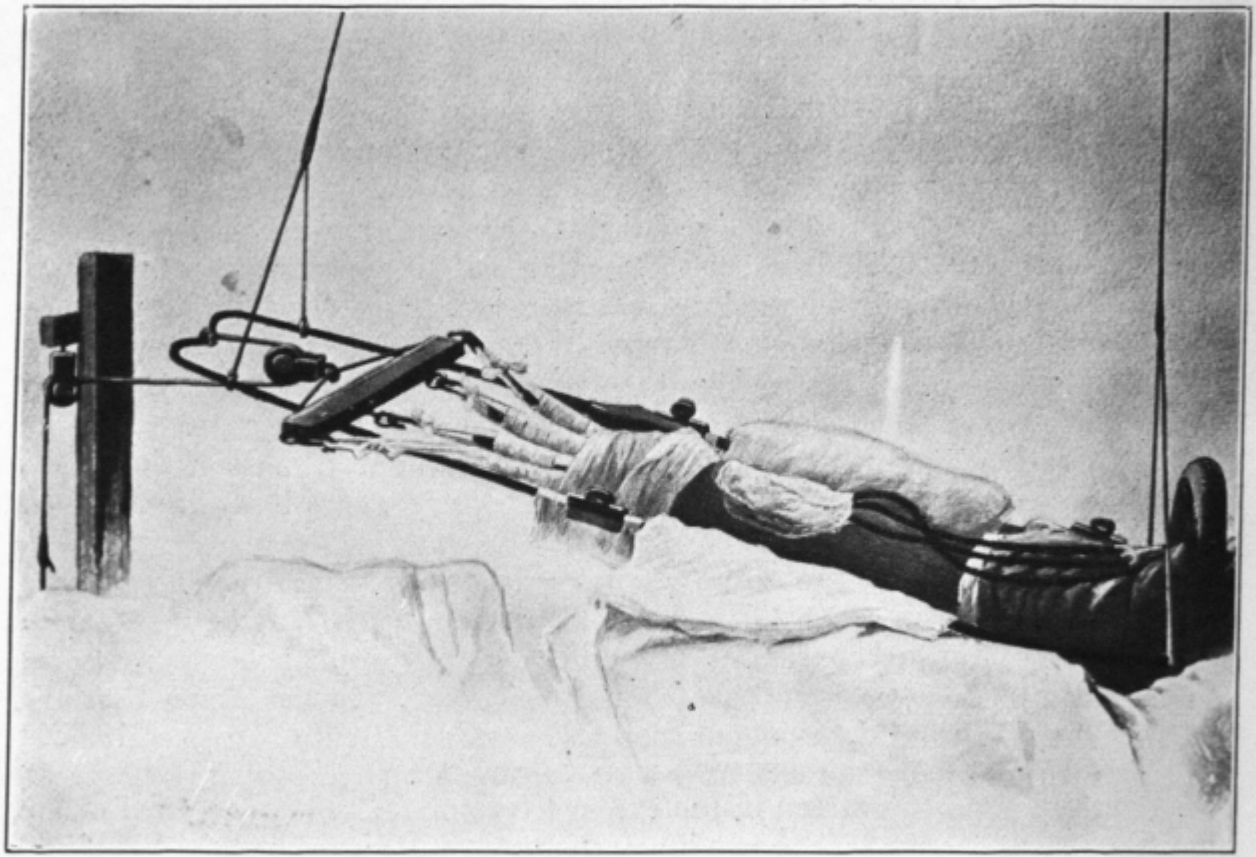

FIG. 74.—Method of treatment of fracture of both bones of forearm