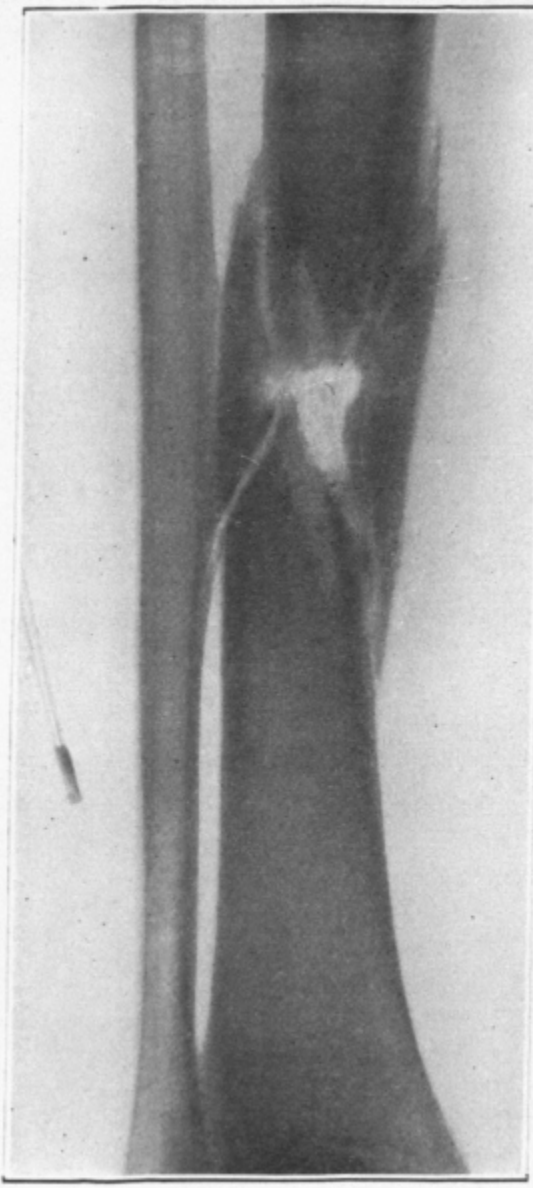

FIG. 65.—Compound, comminuted fracture of shaft of tibia, showing typical "butterfly" arrangement of fragments