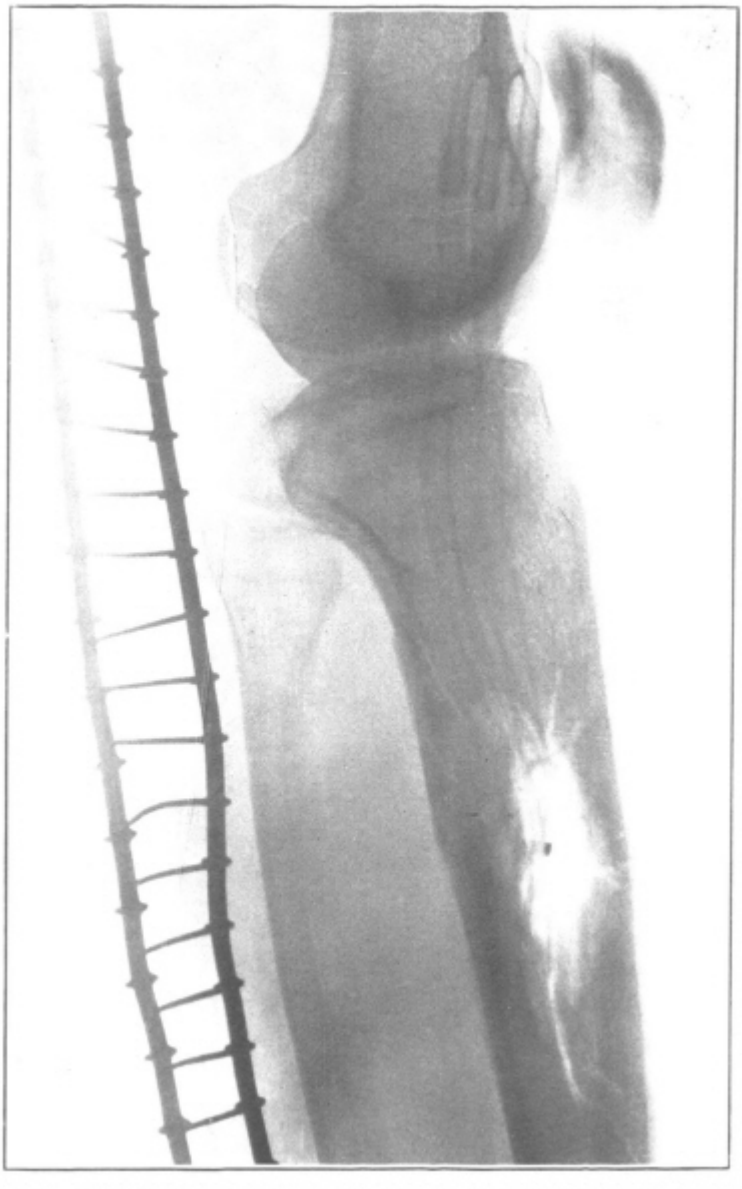

Fig. 63.—Perforating wound of upper portion of shaft of tibia by rifle missile. Much loss of bone shows, but there is little displacement of the bone fragments