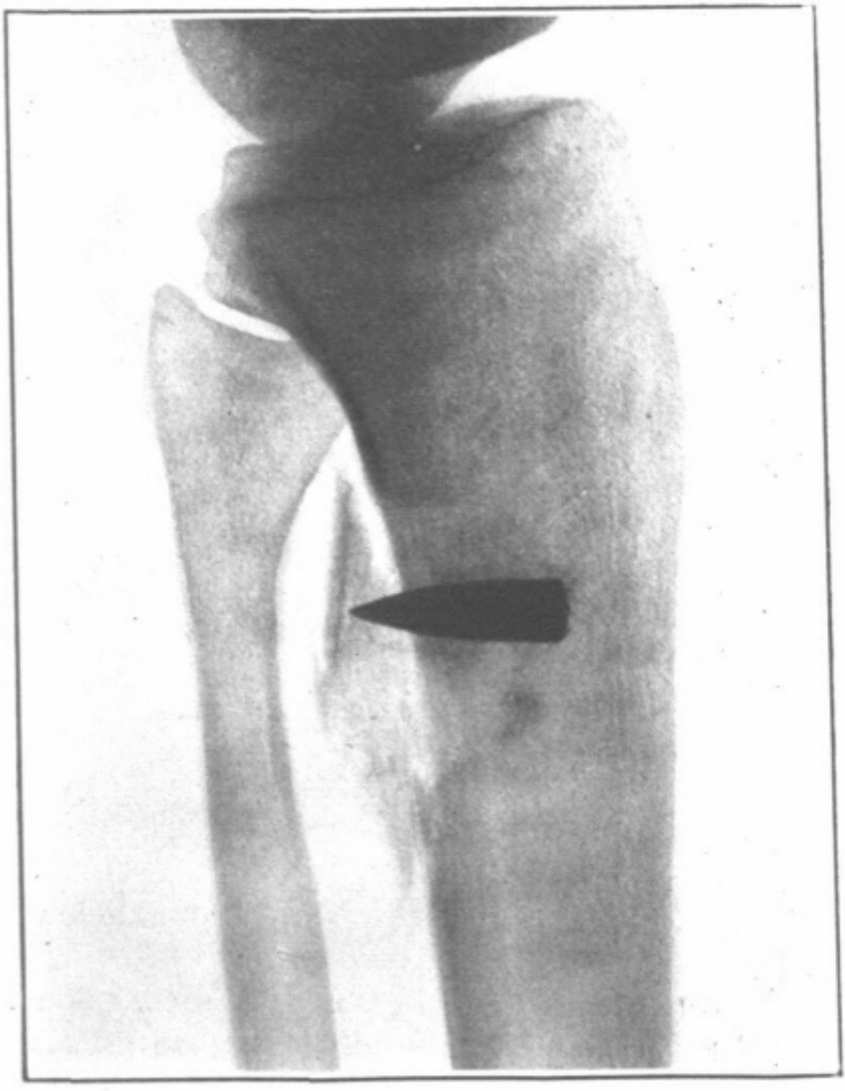

FIG. 61.—Penetration of upper extremity of tibia by rifle missile, with slight detachment of fragment of shaft