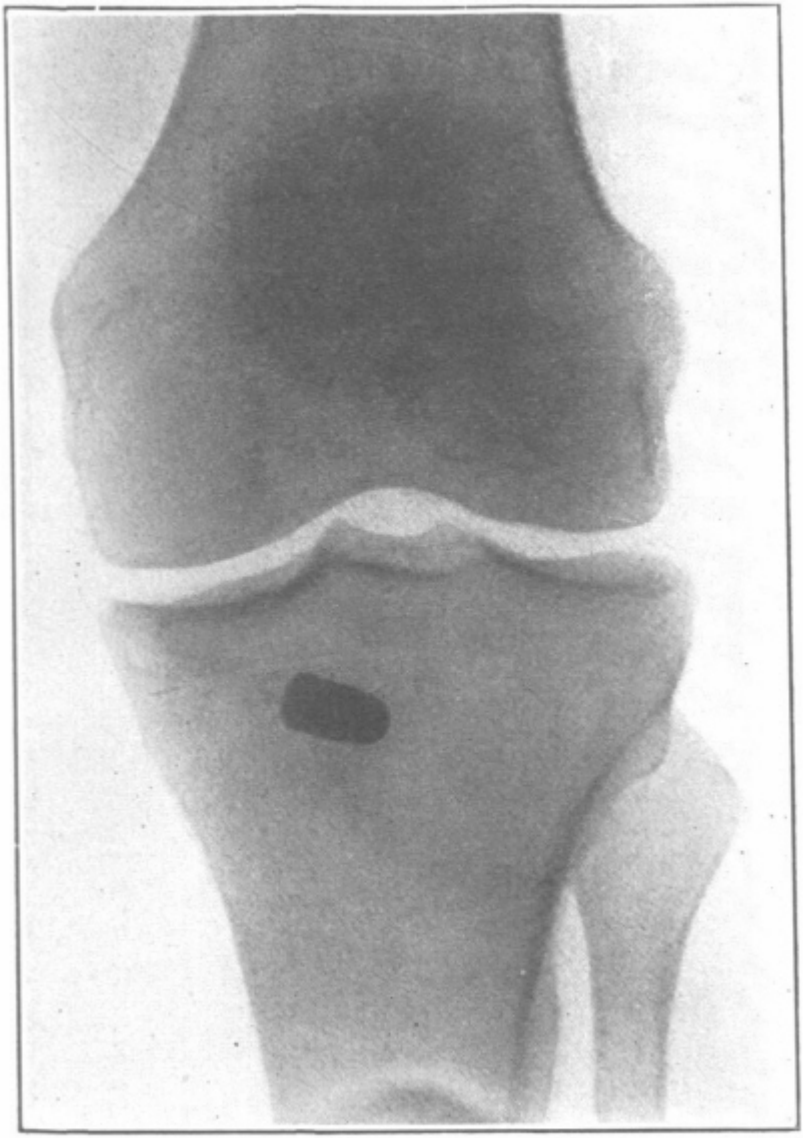

FIG. 59.—Pistol ball wound, head of tibia, showing effect of low-velocity missile on spongy bone. Note tract of missile