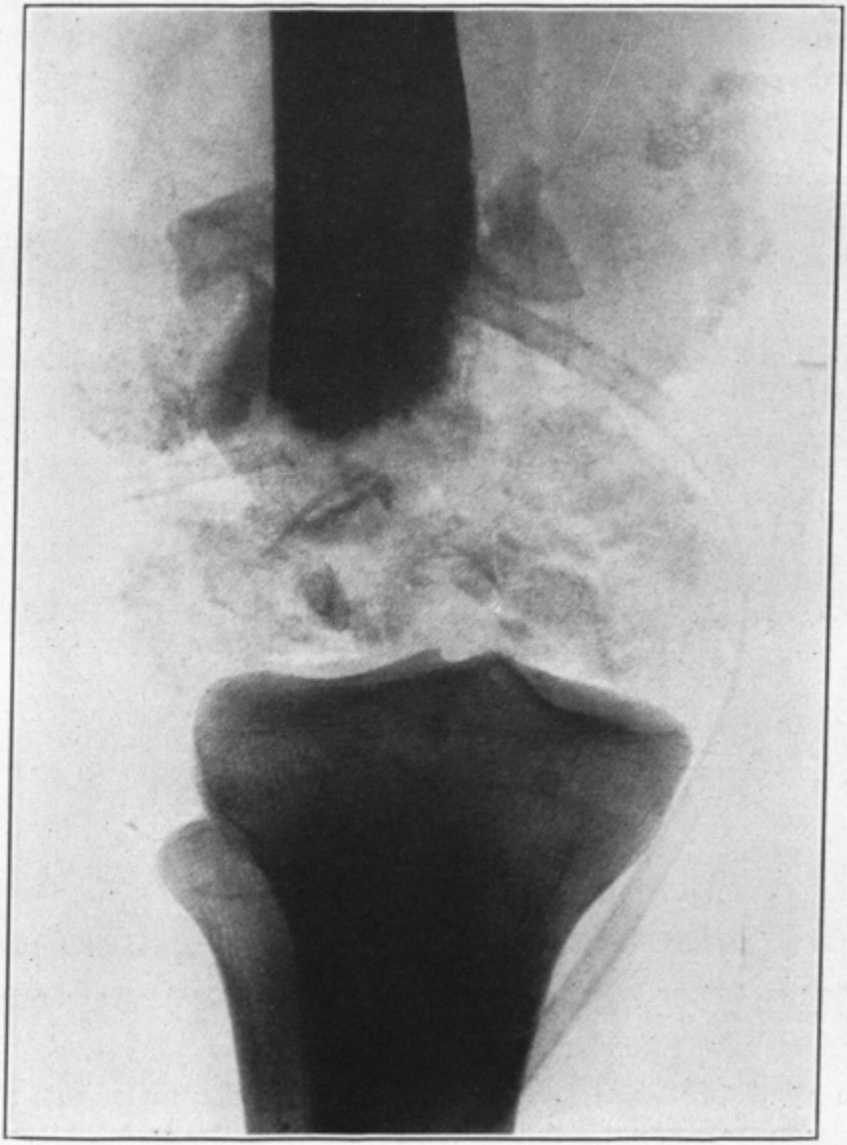

FIG. 58.—Compound, comminuted fracture, lower extremity of femur, with marked dispersion of fragments, resulting in a destruction of both condyles, due to a laterally perforating rifle missile