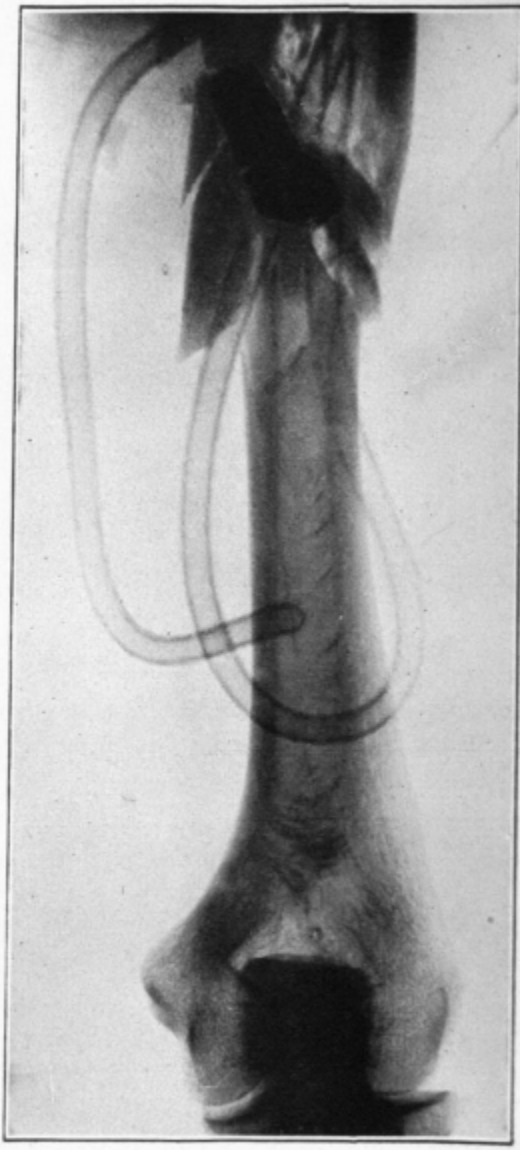

FIG. 48.—Fracture of middle of shaft of humerus by shell fragment; moderate separation of bone fragments. Shell fragment, relatively large, lodged