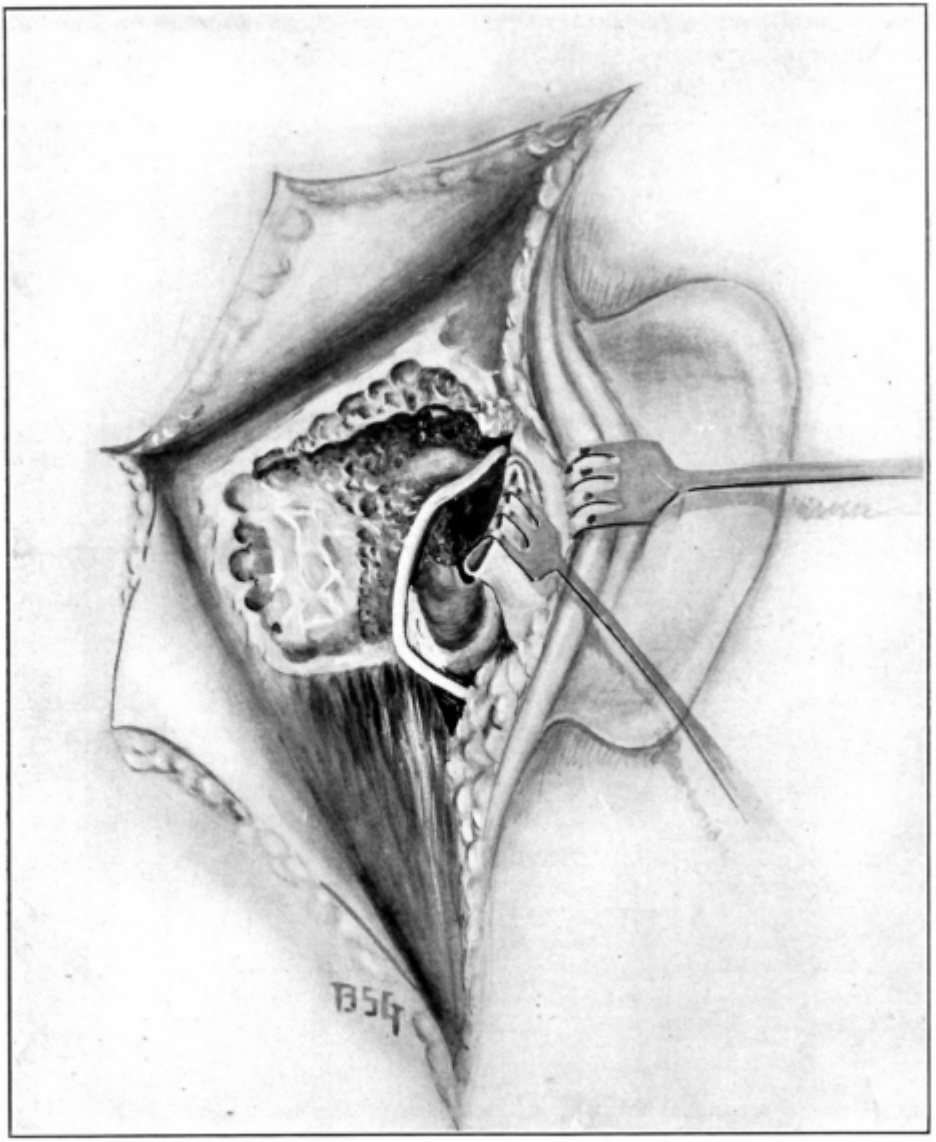

Fig. 206.—The nerve removed from the facial canal throughout its vertical and tympanic course. (Ney. *The Laryngoscope*, 1922)