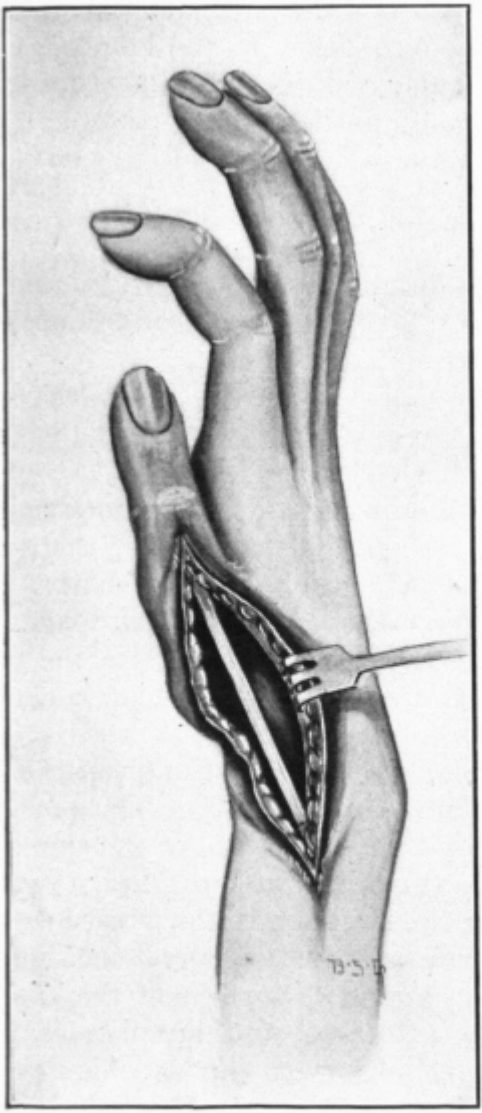

FIG. 189.—Tendon transplant for restoring opponens position and function to the thumb in intrinsic hand muscle paralysis; exposure of short extensor of the thumb