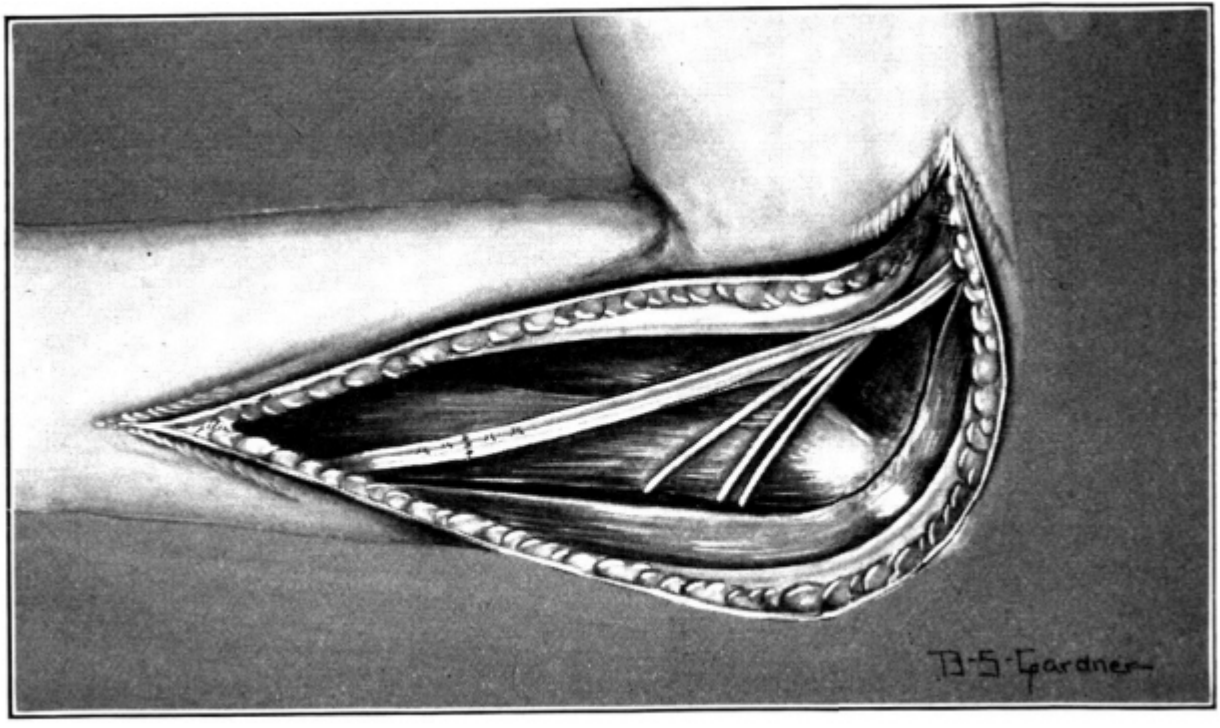

FIG. 185.—Ulnar nerve transposed; defect overcome by transposition and flexion-relaxation of elbow; branches preserved through mobilization