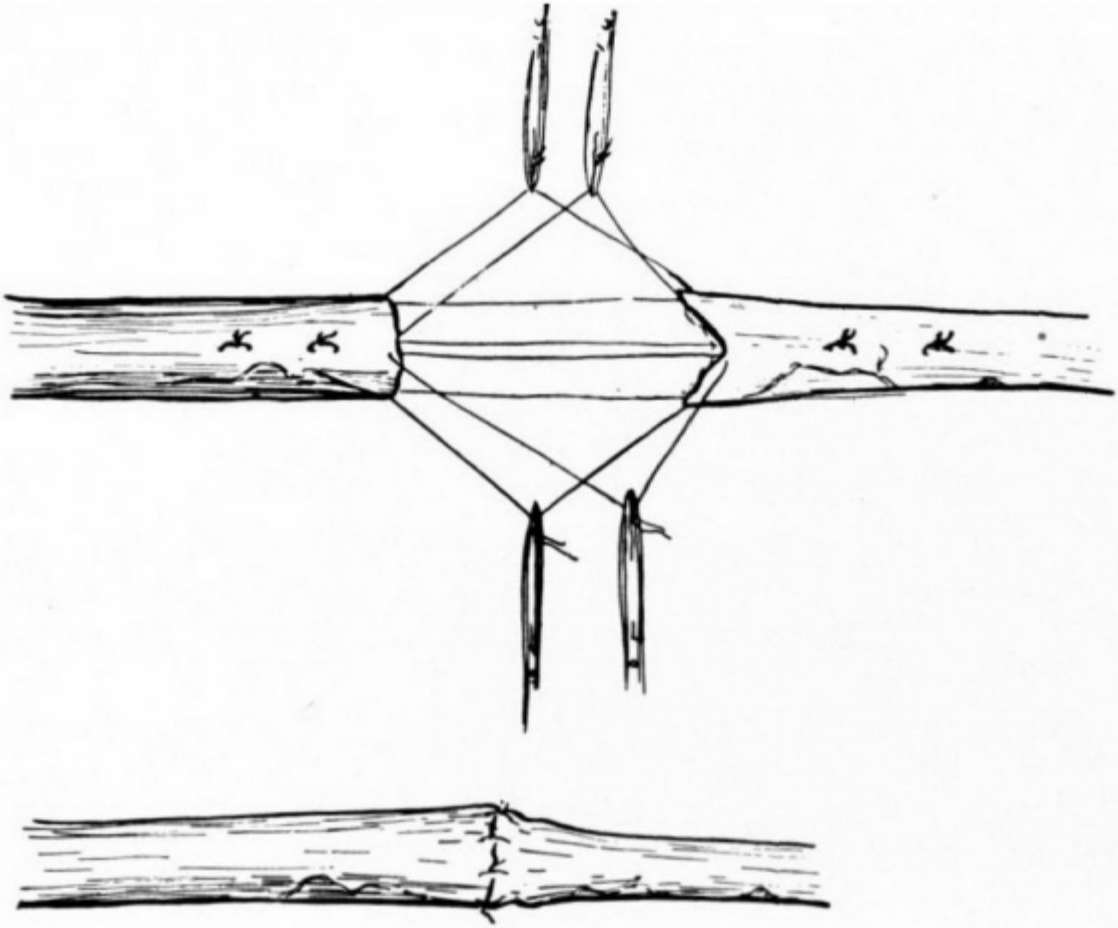

FIG. 158.—The V section of a small distal segment used for the same purpose as the diagonal section in Figure 159. (Ney. *Annals of Surgery*, 1921)