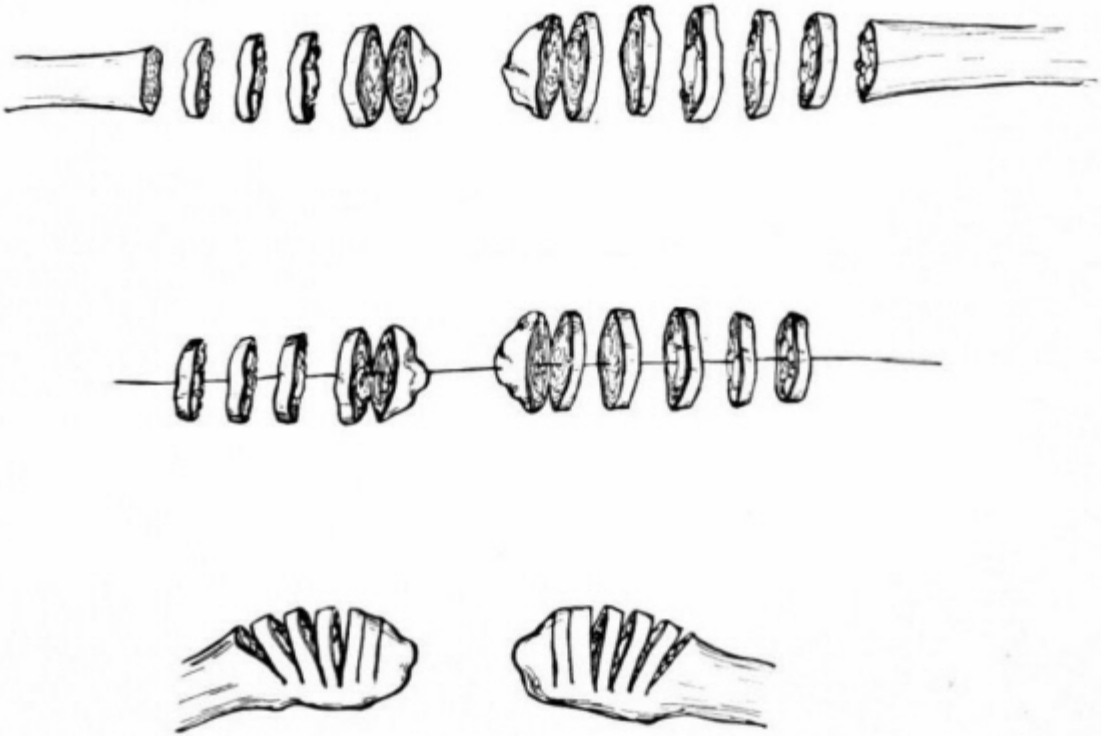

FIG. 154.—Sectioning of nerve ends for removal of neuroma and scar tissue. Method of preserving sections in order of removal. (Ney. *Annals of Surgery*, 1921)