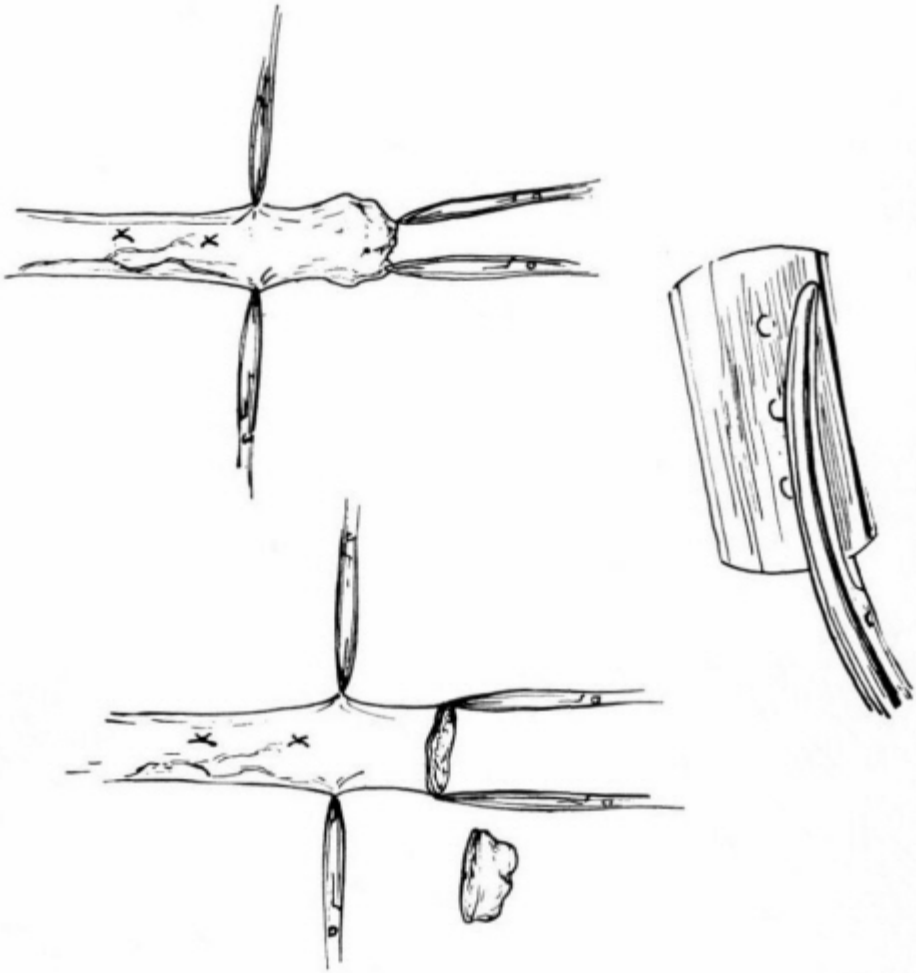

FIG. 153.—Application of forceps to an immobilized nerve during section. (Ney. *Annals of Surgery*, 1921)