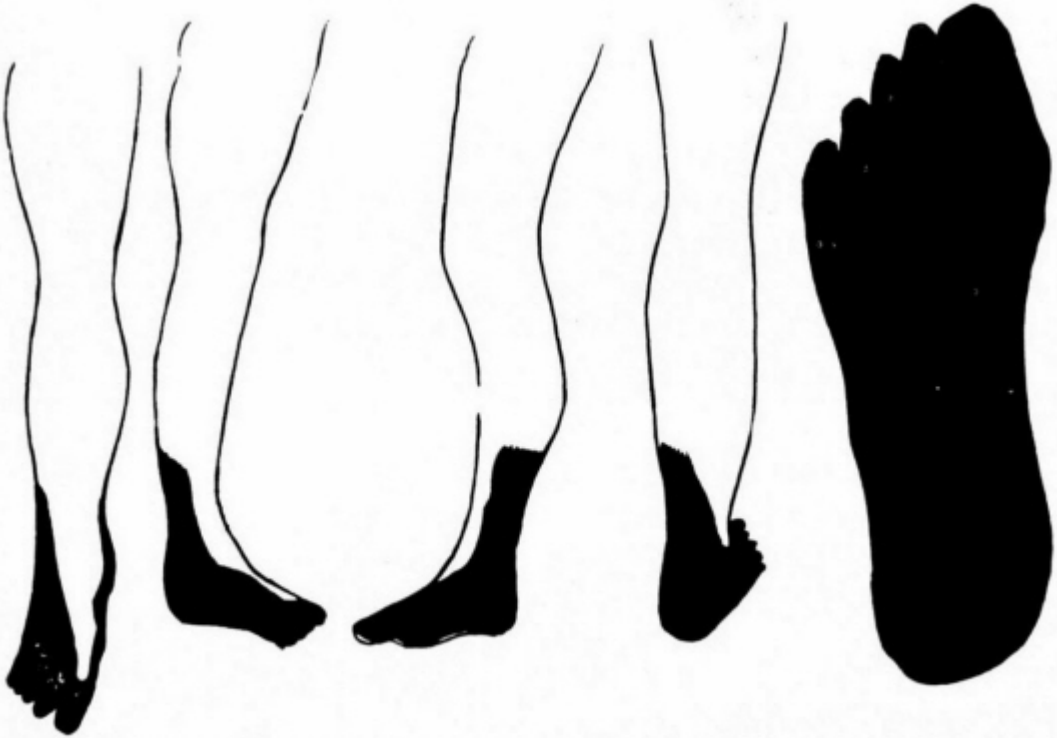

FIG. 148.—Residual sensibility to prick pain of the internal popliteal nerve