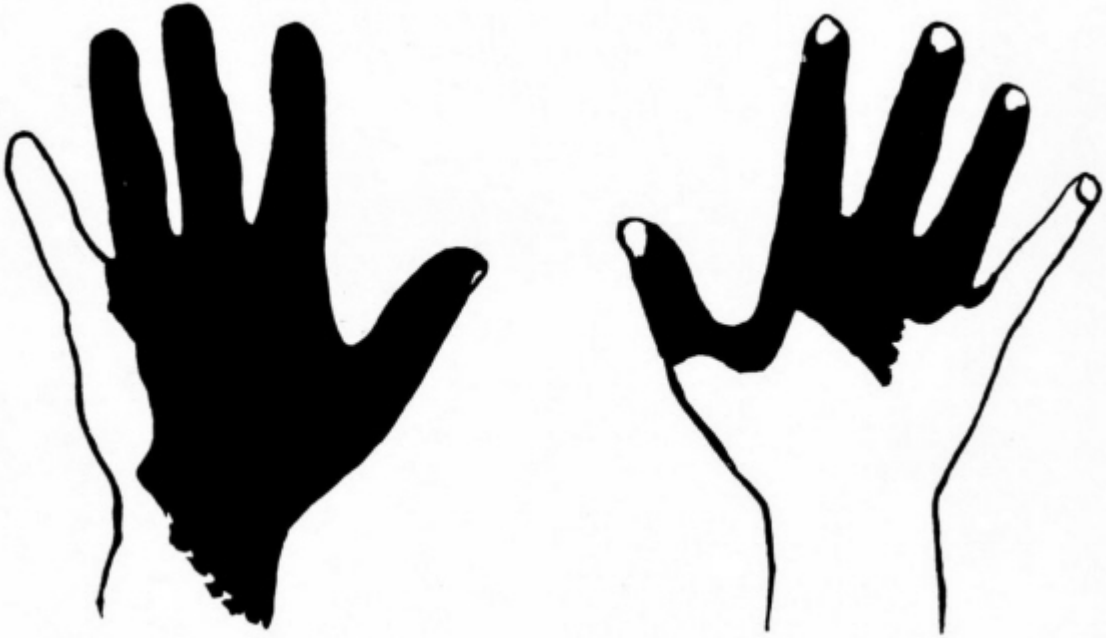

FIG. 143.—Residual sensibility to prick pain of the median nerve