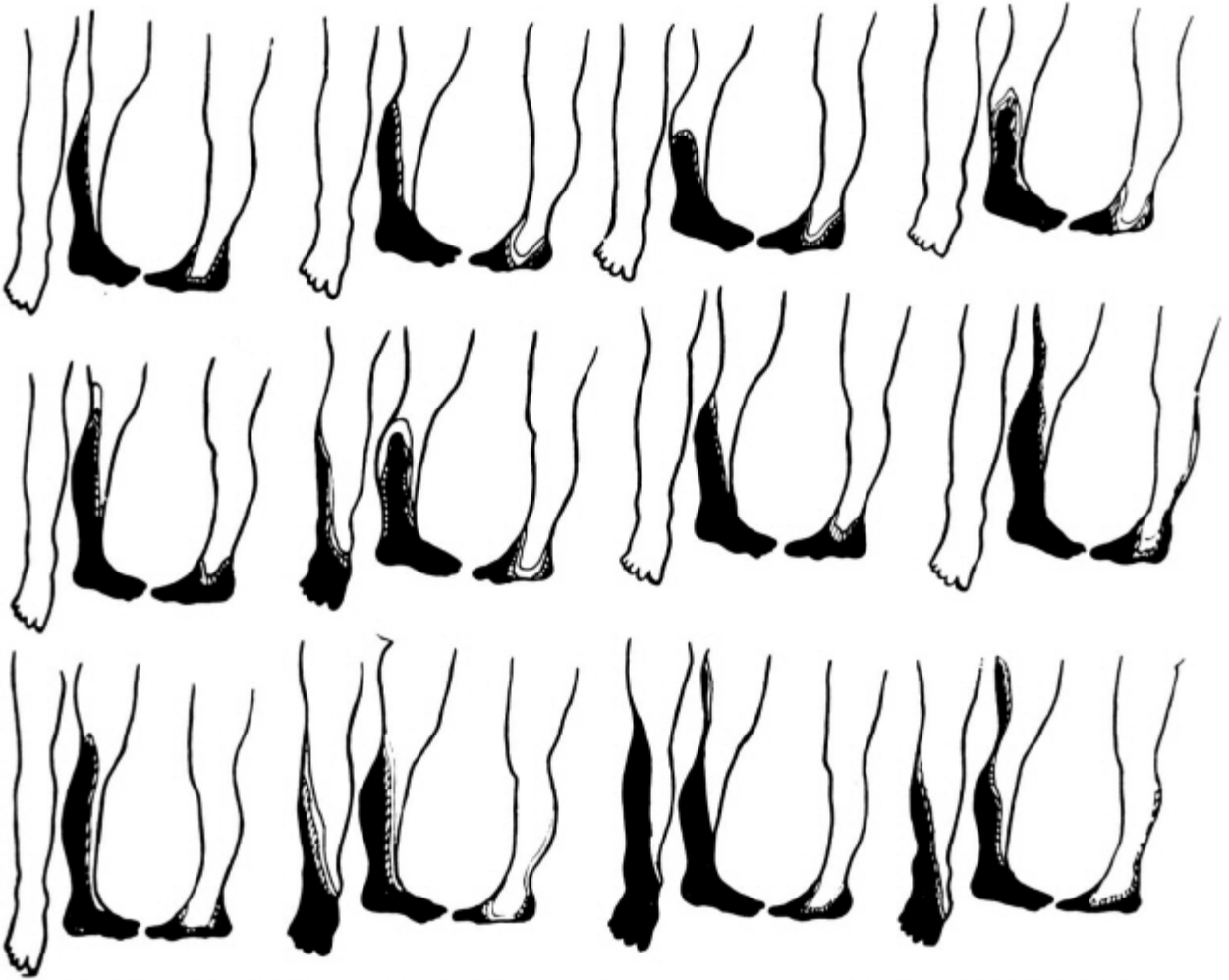

FIG. 138.—Sensory changes in combined lesions of internal and external popliteal portions of sciatic nerve