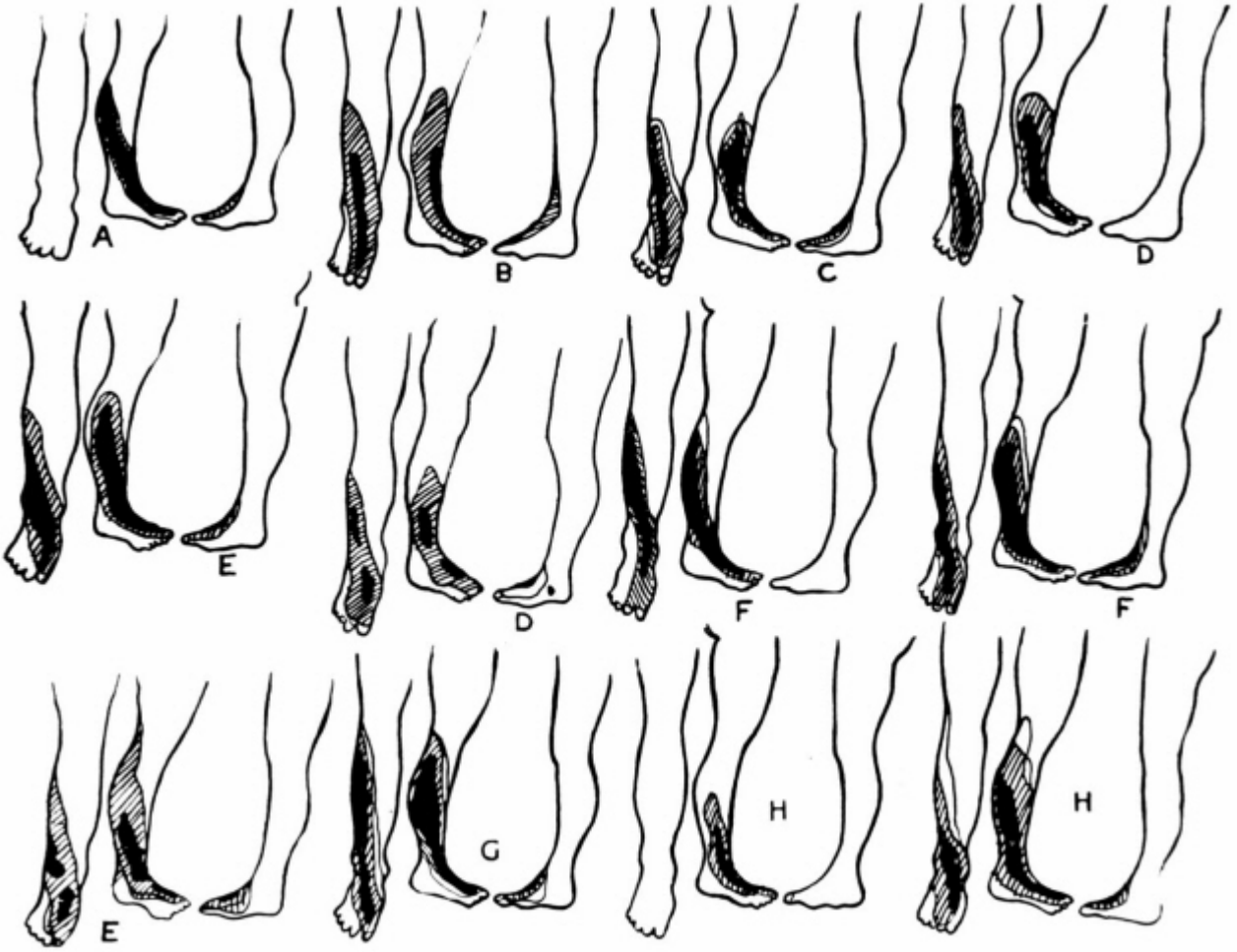

FIG. 132.—Sensory changes in external popliteal lesions