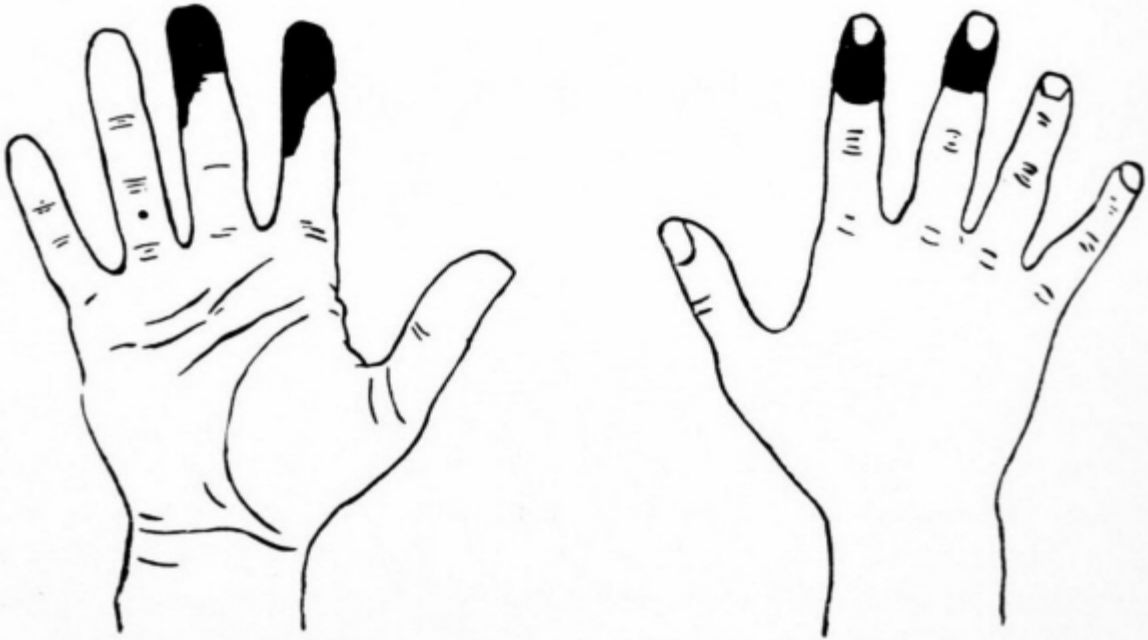

FIG. 130.—Smallest composite area of analgesia in median nerve lesions