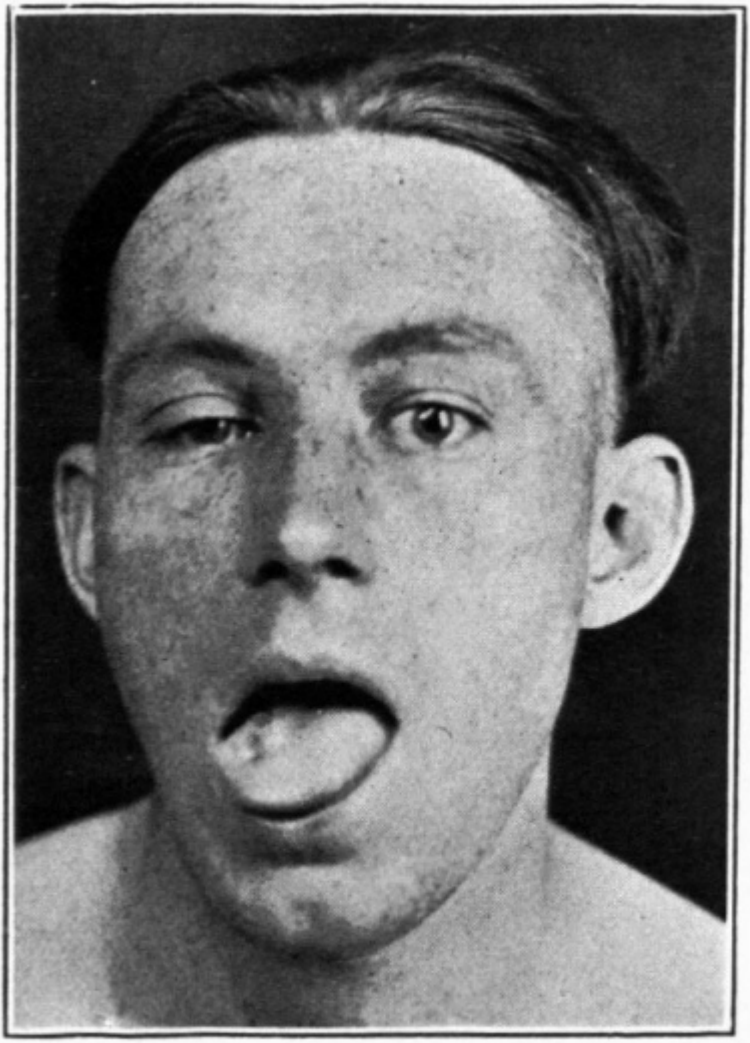

FIG. 126.—Syndrome of the posterior retroparotid space, showing paralysis and atrophy of tongue, narrowing of palpebral fissure, myosis, and enophthalmos