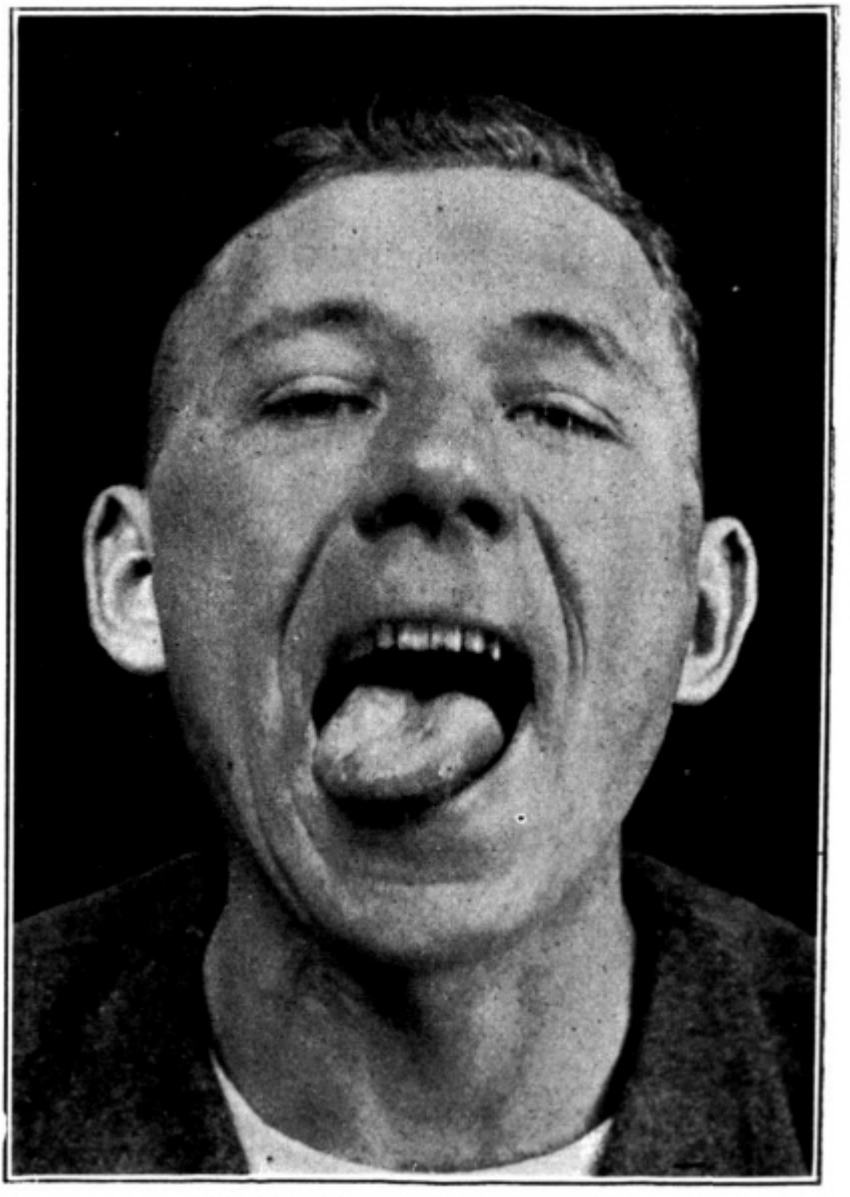

FIG. 125.—Hypoglossal nerve palsy