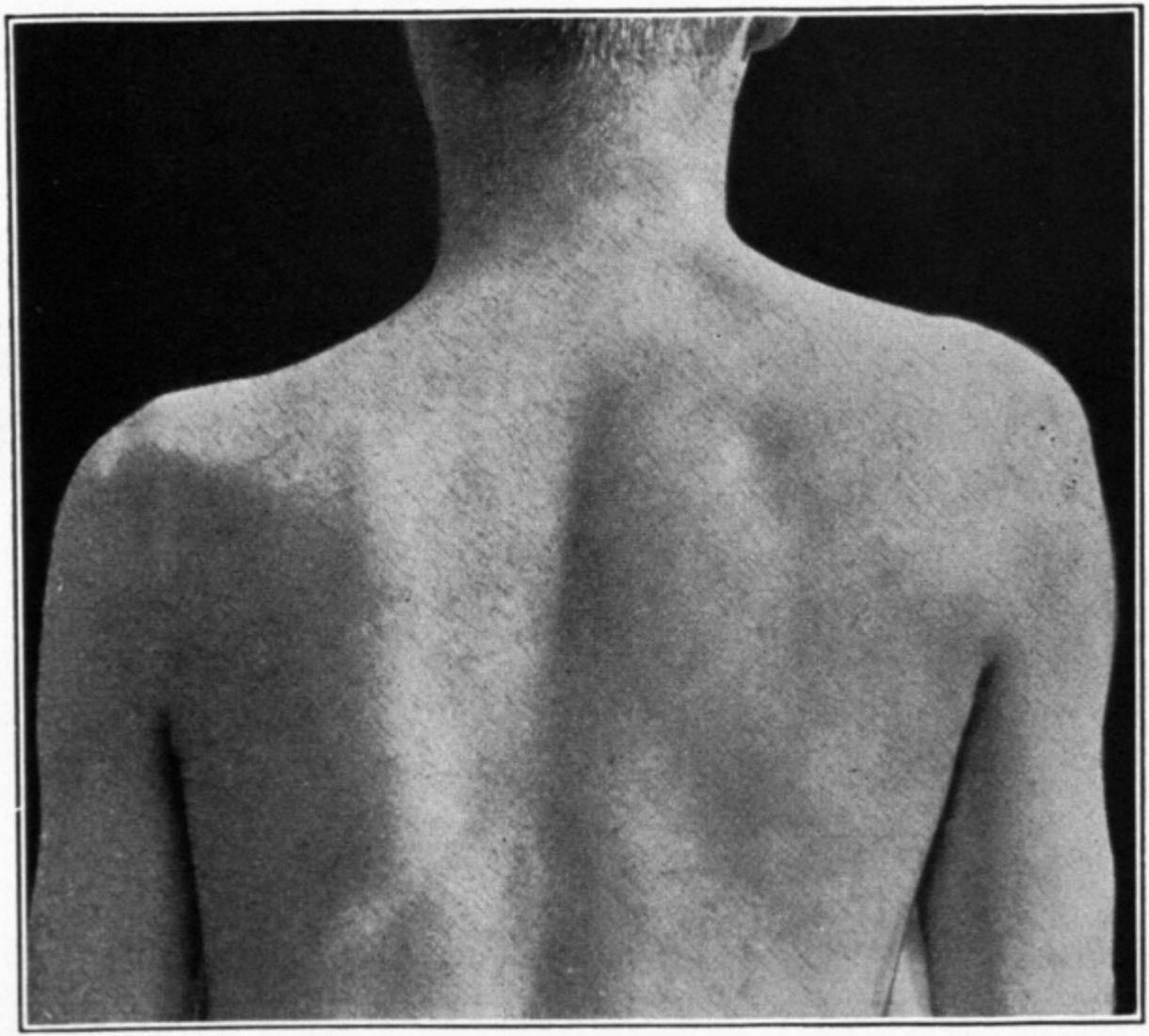

FIG. 124.—Paralysis of trapezius