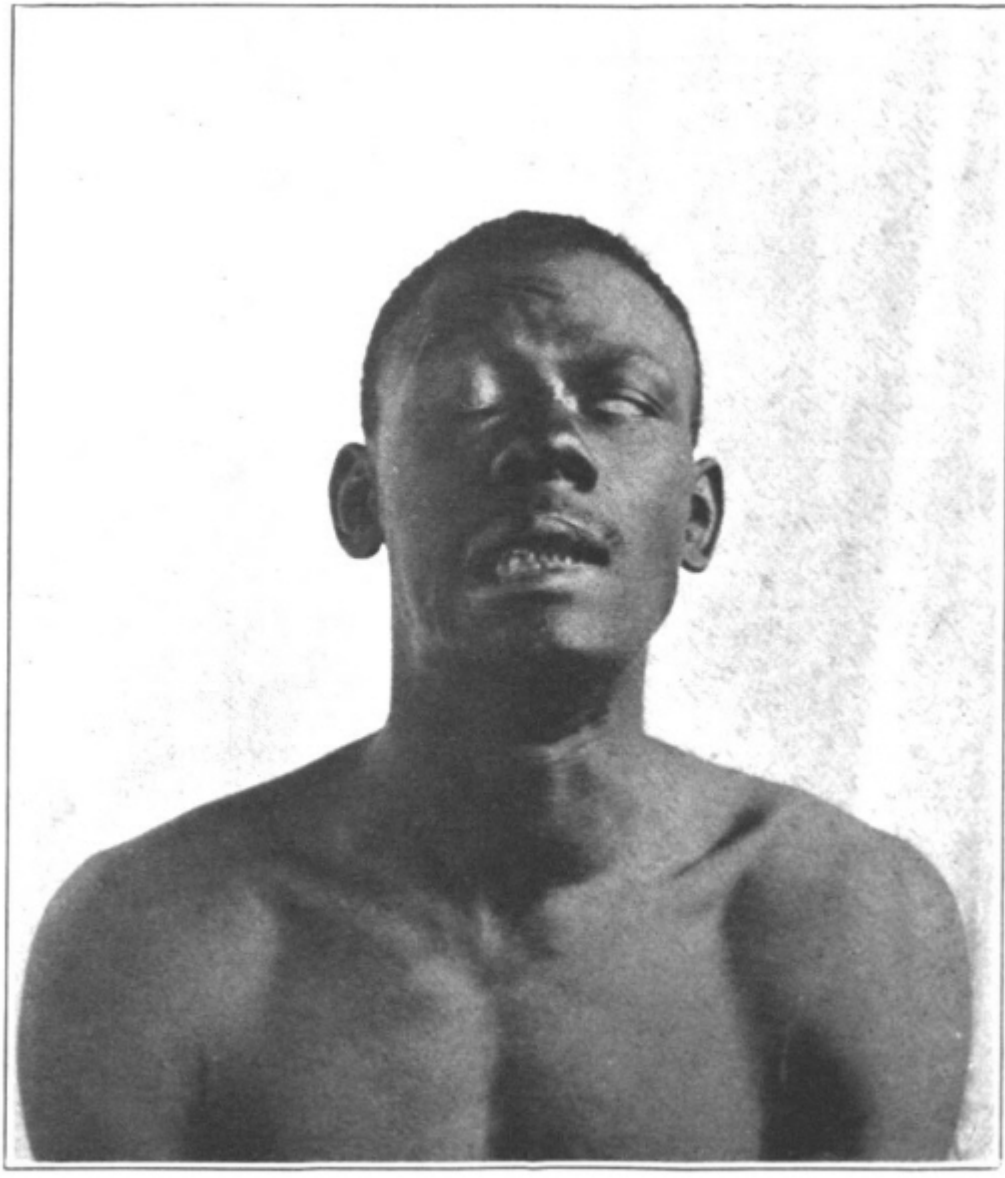

FIG. 123.—Facial palsy