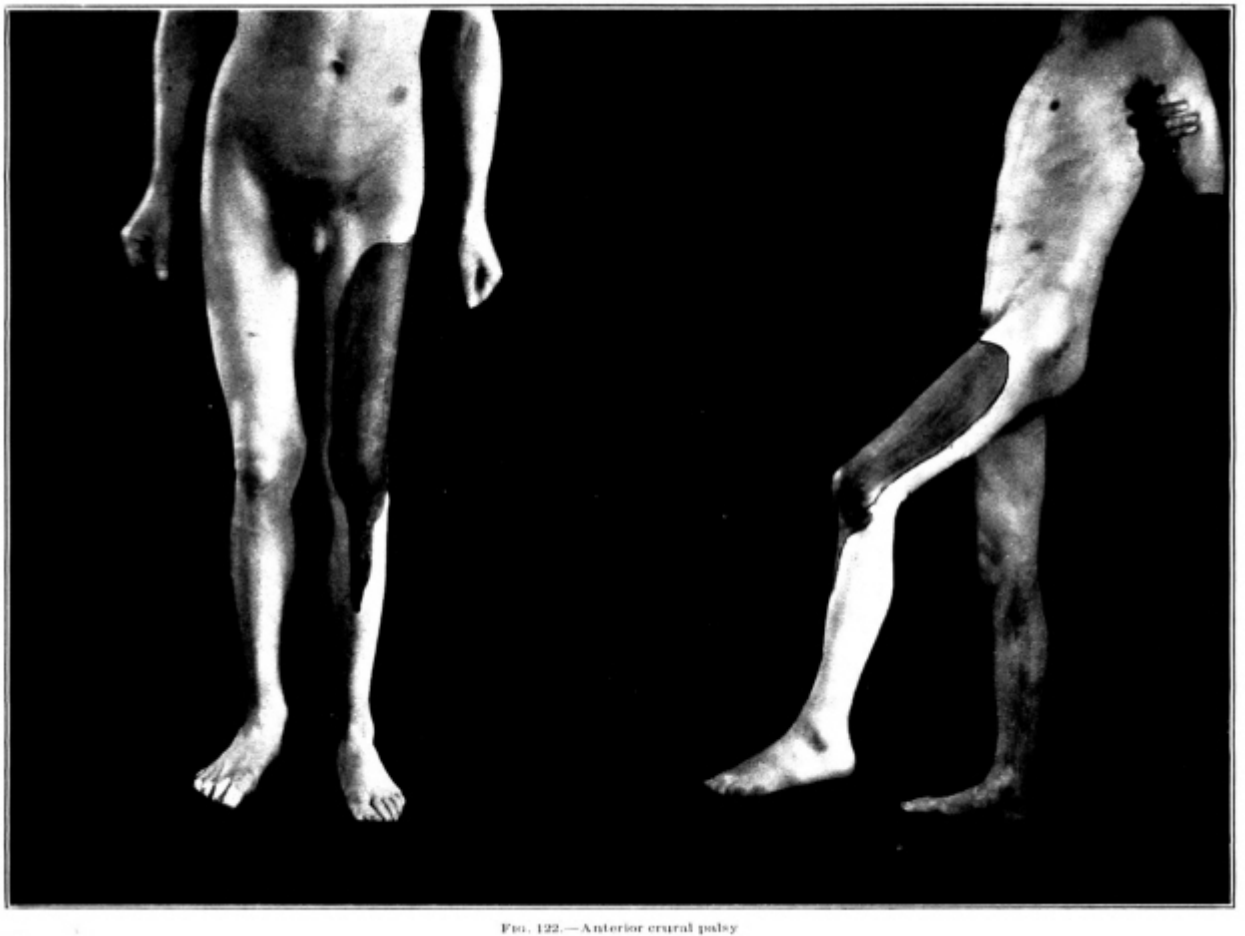

Fig. 122.—Anterior crural palsy