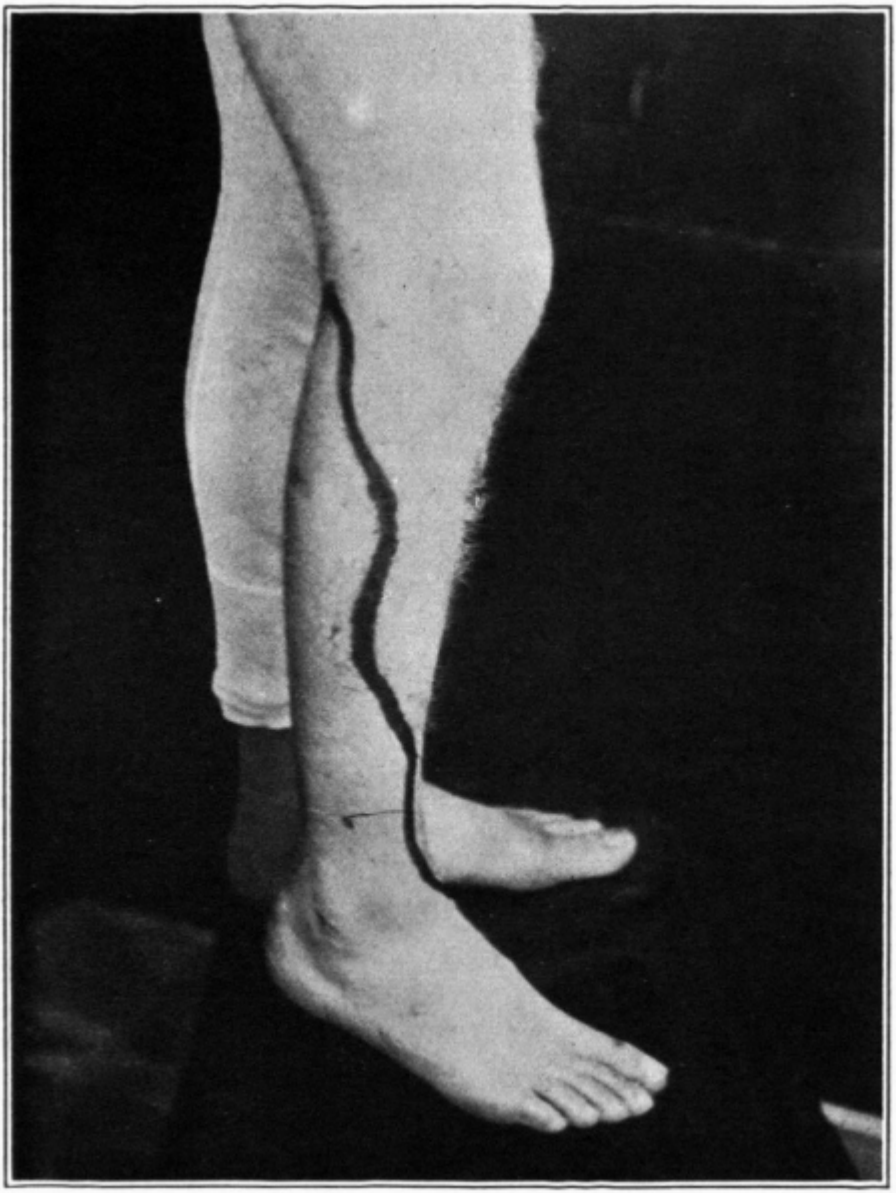

FIG. 120.—Sciatic nerve palsy